22101333179

H. K. LEWIS & Co. LTD.,
NEW AND SECOND-HAND MEDICAL,
SCIENTIFIC AND TECHNICAL BOOKSELLERS,
136, GOWER STREET, LONDON, W.C. 1.

Med
K45103

Digitized by the Internet Archive
in 2016

https://archive.org/details/b28128448

ATLAS AND EPITOME

OF

LABOR AND OPERATIVE OBSTETRICS

BY

DR. OSKAR SCHAEFFER

Privatdocent in Obstetrics and Gynecology in the University of Heidelberg

AUTHORIZED TRANSLATION FROM THE FIFTH REVISED GERMAN EDITION

EDITED BY

J. CLIFTON EDGAR, A.M., M.D.

Professor of Obstetrics and Clinical Midwifery in the Cornell University Medical College; Attending Physician to the Mothers' and Babies' Hospital and the New York Maternity

With 14 Lithographic Plates in Colors, and 139 other Illustrations

LONDON AND PHILADELPHIA

W. B. SAUNDERS & COMPANY

1901

14 774 355

COPYRIGHT, 1901, BY W. B. SAUNDERS & COMPANY

REGISTERED AT STATIONERS' HALL, LONDON, ENGLAND.

WELLCOME INSTITUTE LIBRARY
Coll.
Call No. WQ

PRESS OF
W. B. SAUNDERS & COMPANY

EDITOR'S PREFACE.

THERE is no branch of medicine or surgery, perhaps, that the instructor finds so difficult to demonstrate as that of midwifery; hence any positive aid to his efforts that may be invented or perfected, such as the accompanying ATLAS, is always hailed with satisfaction.

Obstetric surgery is for the most part performed, as it were, in the dark; whereas the gynecologist, by means of improved amphitheaters, the Trendelenburg posture, and electric light, can demonstrate to his audience each step in a given operation. He is enabled to choose his hour for operating, and everything, including the patient, is ready at the appointed time.

On the contrary, a version, the correction of malpresentation or malposition, the removal of an adherent placenta, usually demand that there shall be no delay.

In these comprehensive ATLASES Dr. Schaeffer has added to the multitude of obstetric illustrations already in existence several accurate representations of manipulations and conditions never clearly shown. He is to be congratulated upon his faithful and painstaking work, representing not only the teaching of Professor Winckel, whose assistant he was, but that of modern obstetric art in general.

As an aid to the student in the perusal of his textbook, and as a ready volume of reference for him, or

even for the practitioner at the bedside, I believe the illustrations contained herein will prove invaluable.

In both the *Atlas of Labor* and the *Atlas of Obstetric Diagnosis and Treatment* I have deemed it best to make no additions to the text, and to allow the classification of presentations, positions, and obstetric operations to stand as in the original, although they do not always coincide with those of English and American authorities. In all statements of the French weights and measures, however, the English equivalents have also been given.

J. CLIFTON EDGAR.

50 East 34th Street, New York,
January, 1901.

PREFACE TO THE FIFTH EDITION.

For an explanation of the "programme" of this Atlas, to present the act of parturition and the various obstetric operations in a series of easily understood illustrations, the reader is referred to the accompanying Preface to the Fourth Edition.

This new edition has been enriched by a number of colored plates, added for the purpose of continuing the plan of the *Atlas of Obstetric Diagnosis and Treatment*, which was to give a clear idea of the conditions found on palpation in combination with the anatomic information derived from frozen sections. It is to be remembered that the picture we obtain from frozen sections never quite corresponds to the conditions in the living body, in which the elasticity of the tissues and the functions are preserved. A correct interpretation of hardened anatomic specimens can be obtained only by comparing them with exact observations on parturient patients.

No alterations have been made in the text beyond the addition of a few facts which have been scientifically established since the publication of the last edition.

O. SCHAEFFER.

PREFACE TO THE FOURTH EDITION.

THE demand for this fourth edition shows that the idea of completing the ATLAS by the addition of an epitome on Operative Obstetrics from a practical standpoint has proved acceptable to both the practitioner and the student. With this object in view, I have added to the present edition a number of chapters in which the best methods of inducing premature labor and the surgical obstetric operations are treated as concisely as possible. At the same time the entire text has been carefully revised in accordance with the newest experiences and the latest accepted views and methods.

The subdivision into chapters and sections, which differs somewhat from that ordinarily followed in text-books, is based on certain practical considerations. Thus, the various presentations have been divided not only into favorable and unfavorable, but also into relatively favorable—that is to say, into three groups.

The operations are divided into purely obstetric operations on the fetus and ovum, and surgical obstetric operations on the mother, and further into: (1) preliminary operations, (2) operations during labor, and (3) operations immediately following labor; the various methods in each case being given in the order of their severity and the degree of danger involved. I have done this partly in the belief that it affords the best method of teaching, as I have found in my own courses, and partly to emphasize the warning to the practitioner always to try the most conservative and least dangerous procedure first, as it is the one which offers the best hope of success in by far the great majority of cases.

O. SCHAEFFER.

CONTENTS.

PART A.

The Act of Parturition Considered from the Standpoint of the Practical Obstetrician.

GROUP I.

Positions of the Fetus (Position, Attitude, and Presentation) Favorable for Eutocia.

CHAPTER PAGE

I. Cranial Positions 15
1. Vertex Presentations 17
2. Sinciput Positions 28
II. Face Presentation, Chin Anterior 31
3. Mechanism in the First and Second Face Positions, Chin Anterior 32
III. Breech Positions 34
4. Mechanism of Breech Positions I. and II. 34
5. Tables I., II., III. 38, 39

GROUP II.

Presentations Resulting from Deformities of the Pelvis or Certain Other Typical Conditions which may be Specially Favorable, or at Least not Unfavorable, for such Conditions.

I. The Obliquities of the Cranial Positions 39
6. Solayrè's Obliquity 40
7. Naegele's Obliquity 40
8. Litzmann's Obliquity 42
9. Descent of the Greater Fontanel 44
10. Presentation of the Occipital Bone 44

CHAPTER PAGE
II. Deep Position of the Head in the Transverse Diameter in Vertex and Face Presentations . 46
11. Vertex Positions 46
III. Spontaneous Evolution and Delivery Conduplicato Corpore when the Fetus is Small and in a Transverse Position 47
12. Transverse Position 47

GROUP III.

Positions and Presentations which in themselves Produce Dystocia.

I. Dystocia in Deviations of the Head in Head Presentations 48
13. Presentation of the Sinciput 48
14. Brow Presentation 49
15. Face Presentation, Chin Posterior 50
16. Presentation of the Anterior and of the Posterior Ear 52
II. Unfavorable Presentations in Breech Positions . . 52
17. Footling Presentations 52
18. Abnormal Mode of Escape of the After-coming Head and of the Upper Extremities 53
III. 19. Oblique and Transverse Positions (Shoulder Presentations) 55

PART B.

Obstetric Operations.

GROUP I.

Simple Obstetric Operations on the Fetus and Ovum.

I. Preliminary "Purely Obstetric" Operations on the Fetus and Ovum 62
20. Operations for the Purpose of Correcting the Position of the Fetus 62
21. Replacement of Prolapsed Parts 65

CHAPTER PAGE

22. Rupture of the Membranes and Perforation of the Amniotic Sac 69
23. Version 70
24. Perforation and Cranioclasis; Cephalotripsy . . 76
25. Embryotomy (Decapitation; Exenteration) 78

II. "Purely Obstetric" Operations on the Fetus and Ovum during Labor 79
26. Expression by Pressure on the Abdominal Walls . 80
27. Manual Extraction 80
28. Instrumental Extraction 83
29. Manual Extraction of the Placenta 88
30. Extraction with the Craniotractor, Bone-forceps, or Sharp Hook 88

GROUP II.

Surgical Obstetric Operations on the Mother.

I. Induction of Abortion and Premature Labor . . . 89
31. Methods and Indications 89
II. Surgical Method of Dilating the Parturient Canal 91
32. Episiotomy; Incision of the Portio Vaginalis and Vaginal Fornix. Accouchement Forcé 91
III. Delivery of the Child through Artificial Passages 95
33. Abdominal Section (Celiotomy) 95
34. Symphysiotomy 100
IV. Surgical and other Obstetric Operations Immediately after Completion of Labor . . 101
35. Primary Repair of Perineal Lacerations and of Injuries or Incisions about the Introitus Vaginæ . 101
36. Postpartum Operations Performed upon the Portio Vaginalis through the Speculum 102

PART A.

The Act of Parturition Considered from the Standpoint of the Practical Obstetrician.

INTRODUCTION.

To determine whether the position, attitude, and presentation of an infant are favorable for its birth, it is necessary in every case to consider the size and shape of the infant and of the parturient canal, especially the pelvis, through which it has to pass. If the soft parts are normal, a well-formed, fully-matured infant will be expelled from a pelvis of the usual shape and dimensions with the least amount of risk when it presents with the head; that is to say, in a cranial position in which the posterior portion of the *vertex* is the lowest part as the head passes through the pelvis. A "*vertex presentation*" is therefore the most favorable for normal pelves (Plates 1 and 3). This is not true, however, in the case of pathologic pelves. In generally contracted pelves the occiput is lowest and an "*occipital presentation*" (Fig. 23) takes place. This presentation is the most favorable, because it permits the head to be drawn out into a long, narrow pyramid, corresponding in shape to the generally contracted pelvis. In the flat or anteroposteriorly contracted pelvis, the fronto-occipital diameter of the infant's skull could easily pass the transverse diameter of the pelvic inlet, but the head is too broad for the conjugate. An atypical form of the usual vertex presentation, and one which is much more common than is generally supposed, consists in an upward displacement of the posterior parietal bone along the promontory, so that the sagittal

suture is brought nearer to that structure. But this so-called "Naegele's obliquity" is, as a matter of fact, the most favorable presentation in flat pelves (Plate 9 and Fig. 10 in the text).

The above-described conditions are very simple and can be learned almost mechanically. In every case of dystocia, however, and in all anomalies of position, presentation, and attitude of the child, the conditions are very much more complicated, and the obstetrician must draw his conclusions thoughtfully by a process of reasoning based on analogy before he abandons a waiting policy and resorts to operative procedures designed to assist the natural forces.

There are certain positions and presentations which in themselves constitute absolute indications for operative intervention. Anomalies of attitude do not affect labor unless they produce a faulty position or presentation of the fetus.

The various positions and presentations of the fetus are therefore divided into three groups:[1]

[1] **Classification of Positions and Presentations.**

A. Longitudinal Positions.

I. *Cephalic Positions.*		II. *Breech Positions.*
a. Cranial Positions:	*b.* Face Positions:	
1. Vertex presentation.	1. Chin anterior.	1. Breech presentation.
2. Presentation of anterior fontanel.	2. Chin posterior.	2. Presentation of breech and heels.
3. Brow presentation including the obliquities, presentation of occipital bone, and deep transverse position of the head.		3. Knee presentation. 4. Incomplete footling presentation. 5. Complete footling presentation.

B. Oblique (Shoulder) and Transverse Positions.

The general frequency of positions is as follows:

93.0 per cent. Cranial positions (I. : II. = 2 : 1).
0.8 per cent. Face and brow positions.
4.6 per cent. Breech positions (I. : II. = 1.2 : 1).
1.6 per cent. Oblique and transverse positions.

Group I.—Positions and presentations of the infant *favorable* to eutocia (under physiologic conditions of the parturient canal and of the infant).

1. *Cranial positions.*

(*a*) Vertex positions, or cranial positions I. and II. (Plates 1 to 7, Figs. 1 to 14, 24, and 1, 2 in the text) and their varieties (§ 1).

(*b*) Sinciput positions, mechanism I. with the chin approximated to the breast (presentation of anterior fontanel), or cranial positions III. and IV. (Figs. 25, 26, and 5, 6 in the text) (§ 2).

2. *Face positions*, chin anterior (Figs. 34 to 39, and 7 in the text) (§ 3).

3. *Breech positions* (Figs. 60 to 70 p.p., and 9 in the text) (§ 4).

(*a*) Breech presentation (Plate 8, Fig. 60);

(*b*) Presentation of the breech and heel (Fig. 59);

(*c*) Knee presentation;
(*d*) Complete (Fig. 44) and
(*e*) Incomplete footling presentation (Fig. 86), } less favorable.

Group II.—Presentations produced by pathologic pelves or other typical causes and *favorable* (or not unfavorable) for those special conditions.

1. "*Obliquities*" of cranial positions, slight degrees of which occur quite frequently in normal pelves.

(*a*) Solayrès' obliquity (sagittal suture in the oblique diameter of the pelvic inlet, Fig. 24), occurs as an anomaly in lumbosacrokyphotic funnel-shaped pelves with *oval* inlet, and in generally contracted pelves;

(*b*) Rotation of the sagittal suture into the conjugate of the pelvic inlet (§ 6);

(*c*) Naegele's presentation of the anterior parietal bone (presentation of the anterior ear (Fig. 21, and Fig. 10 in the text) (§ 7);

(*d*) Litzmann's presentation of the posterior parietal bone (presentation of the posterior ear), as a rule less favorable (Fig. 22 and 11 in the text) (§ 8);

(*e*) Descent of the greater fontanel (Plate 9, Fig. 27) (§ 9);

These three (*c–e*) occur in flat anteroposteriorly contracted pelves.

(*f*) Roederer's presentation of the occipital bone (Fig. 23) in generally equally contracted pelves, often combined with *a* and *b* (§ 10).

2. Deep transverse position in cranial (Fig. 12 in the text) and face positions (§ 11).

3. When the fetus is small and in an oblique position, "spontaneous evolution" and escape *conduplicato corpore* (Figs. 52 to 56) (§ 12).

Group III.—Positions and presentations of the child which *in themselves produce dystocia:*

1. In *cephalic positions:* insufficient flexion.

(*a*) Arrest of one side of the head on the iliac bone (compare § 23 C) and subsequent deviations *b–d.*[1]

(*b*) Presentation of the *sinciput*, mechanism II. with the chin away from the chest (under abnormal conditions of resistance, Figs. 27, 28) (§ 13);

(*c*) *Brow* presentation when the head is large, especially with the chin posterior (Figs. 29 to 33, and 30 in the text) (§ 14);

(*d*) *Face* presentation, chin *posterior* (Figs. 40 to 42, and 8 in the text) (§ 15);

(*e*) Arrest at the center of the pelvic inlet (§ 23 C) and extreme lateral deviation as in *f:*

(*f*) Presentation of the anterior and of the posterior ear (§ 16).

(*g*) Arrest of the head between the promontory and the pubic bone (flat pelves);

(*h*) Arrest of the head in the true pelvis (generally contracted) = paragomphosis (comp. presentation of the occipital bone and § 23 C);

(*i*) *Prolapse of an extremity* (blocking the passage of the head).

2. In *breech positions:*

[1] "Extramedian" engagement of head. (?)

(*a*) With *posterior* rotation of the aftercoming occiput (§ 18):

(*α*) Chin flexed on the breast; face born first (Fig. 93) (more favorable);

(*β*) Chin *extended*, occiput born first (Fig. 92).

(*b*) Prolapse and wedging of the anterior arm (§ 18).

(*c*) Footling positions (Plate 11, Figs. 44 and 86) (§ 17).

3. *Oblique* and *transverse positions* (usually shoulder presentations) (Plate 10, Fig. 48 p.p., 75 p.p.) (§ 19).

GROUP I.

Positions of the Fetus (Position, Attitude, and Presentation) favorable for Eutocia.

CHAPTER I.

CRANIAL POSITIONS.

These are either *straight* or *longitudinal* positions; that is to say, the long axis of the child lies in the direction of the long axis of the parturient canal (definition of longitudinal positions) and stands "straight," that is, perpendicularly over the pelvic inlet.

The commonest positions of the fetus are the cranial positions: The posterior portion of the cranium or vertex "engages" in the true pelvis and is therefore found "presenting" on palpation. These *positions* (situs) are the most favorable because the head, owing to its uniform circular contour, dilates the soft parts with the least amount of injury (next to the amniotic sac), and because, after this the largest portion of the head has escaped, the fetal trunk follows without difficulty. The *vertex presentation* is the most favorable because in this presentation the smallest periphery of the head passes the conjugate (suboccipitobregmatic = $12\frac{5}{8}$ in. or 32 cm.) and the head

in this attitude admits of the greatest possible movement of the vertical column, so that the latter adapts itself to the curve of the pelvic axis.[1]

The fetal back is found twice as often in the *left*, as in the right side of the mother's abdomen.[2] This *position* (positio) in all *longitudinal positions* is designated as subvariety I., while that with the back on the right side is designated II. Thus we distinguish *cranial positions* I. and II.

In *cranial position* I., therefore, the fetal back is found on the left, and the extremities on the right side; and when the uterus is in a state of rest, the back lies posteriorly, so that the heart-sounds coming from the fetal chest are heard between the extremities (comp. Plates 2 and 4). The usual *attitude* of the child—that is to say, the relations of the individual portions of the fetal body to the trunk and to each other (definition)—is due to the adaptation of the fetal body to the ovoid shape of the uterine cavity and to the greater flexibility of the trunk and extremities as compared with that of the head, the fetus naturally assuming that attitude in which it occupies the least amount of room. The fetus itself plays a passive part. The elasticity of the uterus permits it to expand in every direction, but at the same time the active contraction of the uterine muscle tends to push into the lower

[1] A curved line uniting the centers of all the conjugates from the pelvic inlet to the outlet.

[2] *Causes.*—Oblique position of the uterus, the left border of which is usually tilted forward, combined with the lumbar lordosis of the vertebral column and the physiologic dextroposition of the uterus. Toward the last weeks of pregnancy the fetal back may be situated posteriorly, or may alternate between the two positions; hence the anatomic causes just referred to do not exert their full influence until labor-pains begin and the fetal back is forced forward. The posterior position of the back is due to the effect of gravity, the right side of the child, owing to the weight of the liver, being the heavier (comp. Plates 2 and 4 with 1, 3, 5, etc.). In cranial position II. (fetal back on the right side) the back is not rotated anteriorly so much, and anterior rotations of the sinciput, leading to presentations of the greater fontanel, are more apt to take place. In Japanese women it is said that II. is more frequent than I. In lumbosacrokyphotic funnel-shaped pelves the two positions occur with equal frequency and are more common than sinciput positions at the pelvic inlet.

uterine segment, where the contractions are slight, that part which is most easily seized and offers the greatest resistance: in other words, the head (comp. Plates 2, 3, and 6).

As the head becomes larger and firmer in each successive month of pregnancy, the probability of cranial positions increases as the end of pregnancy is approached.

In this way the child assumes a longitudinal position with the head presenting. The cause is, therefore, to be sought in the pyriform shape of the uterus. The back is curved, the extremities are flexed at every joint and fill the cavity of the anterior aspect of the trunk between the head, which is flexed with the chin on the breast, and the breech. The arms are folded on the breast, the legs lie close to the abdomen (Plate 1).

The *physiologic attitude* as shown in Fig. 4 is necessary not only to insure the birth of the infant in a favorable position, but also to permit the head to engage at the pelvic inlet in the position most favorable for the expulsion of the infant, or, in other words, to bring the various peripheries or diameters of the presenting part into the necessary relations with the diameters of the pelvis (sagittal suture, vertical line of the face, transverse diameter of the fetal pelvis), and finally, to bring the characteristic portions of the presenting part, such as the fontanels and the chin, within reach of the palpating finger (Figs. 1–13 in the text).

§ 1. **Vertex Presentations (Cranial positions I. and II.). Mechanism and Management of Normal Labor** (Figs. 1–20, Plates 1–7).

Labor begins with the separation of the pole of the embryo from the uterine wall (palpation of the tip of the amniotic sac in the cervical canal, beginning dilatation of the internal os, slight hemorrhage), and in primiparæ with dilatation of the external os (Plates 3 and 4, Fig. 1) which in multiparæ begins to dilate in the fifth month (Fig. 2). The head enters the lower uterine segment.

Plate 1.

Condition found on Palpation at the End of Pregnancy in a Multipara.

The abdominal walls are relaxed and there may even be pendulous abdomen. The uterus is still quite elastic and accordingly tense (uterus fusiformis). It is displaced slightly to the right, as usual, and its left border is rotated forward so that the left round ligament can be readily palpated. Owing to the pendulous abdomen, we feel in the fundus the entire breech and both thighs, which appear to be forced up against the abdominal wall and the palpating hand. The back is turned to the right, so that we can only feel its left border: the head has already entered the pelvic inlet, owing to the tension of the uterine muscle-fibers. Only a small segment which has become arrested at the inlet can be felt. The heart-sounds are heard to the right of the linea alba, corresponding to the left border of the back (cranial position II). Note the physiologic attitude of the extremities in relation to the trunk.

Plate 2.

Condition found on Palpation at the End of Pregnancy in a Multipara with tense abdominal walls and relaxed uterus.

As the result of gravity, the woman being in the dorsal position, the fetal back is behind and on the right side, so that the four extremities are easily palpated in front, and the heart-sounds are heard more in the median line and with greater uniformity over a large area of the abdominal wall, differing in this respect from their behavior in position II. of the back. As usual in multiparæ, before the onset of labor-pains the head is still movable above or within the pelvic inlet. Usually it is placed with its anteroposterior diameter in the transverse diameter of the pelvis. The flaccid condition of the uterine muscle is recognized by the remarkable ease with which the extremities can be palpated and the free movements of the latter; thus, in the picture, for instance, we see the left leg almost extended and bulging out the anterior wall of the fundus.

In multiparæ it now begins to engage in the true pelvis: in primiparæ the engagement of the head has already taken place, owing to the tense condition of the abdominal walls (compare Plate 2 with 1, 3, etc., Fig. 1, 2). The true dilatation-pains (*dolores præparantes*), recognized as vigorous contractions of the hardened uterus, now make their appearance and the contraction-ring (Plates 6 and 7) rises above the pelvic inlet.[1]

[1] If the contraction-ring is found a hand's breadth above the symphysis, or at the level of the umbilicus, it is a sign of danger to the excessively dilated lower uterine segment.

Differences in the onset of labor:[1]

The methods of external and internal examination are described in the *Atlas of Obstetric Diagnosis and Treatment*, second edition, Chapters I. to III.

By external examination (palpation and auscultation) we determine the presence of a living child, its position, and the engagement of the presenting part—in this case the head—in the true pelvis; the back on the left side, the extremities on the right; the heart-sounds are audible to the left, midway between the umbilicus and the anterior superior spine of the ilium. As the anterior wall of the uterus becomes very much attenuated toward the end of pregnancy (*segmentum chartaceum*), we are able to recognize the sutures and fontanels by palpation through the anterior vaginal fornix, and can therefore determine the position of the presenting part at this time even before the descent of the amniotic sac.

Condition found on palpation when the head is engaged in the pelvic inlet in **vertex presentation I.** (Plates 1 and 2, Fig. 3): External os as indicated in primiparæ and multiparæ (see below). Sagittal suture in the transverse

[1] Labor at term occurs in the thirty-eighth to forty-first week, determined by counting back three months from the last menstruation and adding seven days. Mean duration of pregnancy, 265 to 280 days (to 302 days).

Primiparæ (Fig. 1).	Multiparæ (Fig. 2).
Vulva: Gapes slightly.	Gapes; possible scars.
Vagina: Contracted and rough.	Wide, soft, and smooth.
Portio: Soft, flaccid cone.	Soft swollen mass instead of a cone.
External os: Sharp edge; closed till the ninth month; after that, admits the distal phalanx.	Open from the fifth month; absence of sharp edge, fissured.
If patulous, labor within a few days.	If the cervical canal is patulous, labor may be expected in two weeks.
Internal os: Closed. Often dilated before the external os; opens sub partu together with the cervix before the external os.	Begins to dilate in the ninth month.
Head in the true pelvis toward the end of pregnancy.	Until the onset of labor, the head is above the pelvic inlet, or imperfectly engaged in the true pelvis and quite movable.

Plate 3.

Vertex Position I. in the Dilatation-Stage, during a Labor-pain (sagittal section through the trunk). The uterus is rigid, the fetal back is rotated forward (left), the fetal trunk is extended, the fundus uteri is closely applied to the breech. The cervical canal is dilated from within outward by the labor-pain, and the amniotic sac is forced into it. The head is completely engaged in the true pelvis, the occiput to the left and in front (L. O. A.).

Plate 4.

Vertex Position II. in the Dilatation-Stage, during an interval between Labor-pains.—The uterus is relaxed and the longitudinal diameter shortened. It is closely applied to the fetal parts and to the adjacent maternal organs. Thus, for instance, it is indented opposite the symphysis and forms a sacculation at this point. The fetal back has returned to the right posterior portion of the uterus (position II., where it is regularly found toward the end of pregnancy and during the onset of labor. The child has assumed an attitude of lateroflexion and is, as it were, collapsed. The attitude is shown by a temporary extramedian position of the sagittal suture, found on palpating the presenting head. The head is held fast with its greatest circumference in the diagonal of the plane of pelvic expansion. Owing to the lateral deviation of the sagittal suture, a large portion of the right parietal bone is palpable. The cervix and the amniotic sac are also relaxed.

diameter of the pelvis. Lesser fontanel and fetal back on the *left*. The sagittal suture between the greater and lesser fontanel presents in front. The parietal bones are at the same level, the sagittal suture usually lies midway between the symphysis and the promontory.

Naegele's, Litzmann's, and Solayrès' obliquities not rarely occur; Roederer's obliquity is less frequent: N. O.: the sagittal suture is nearer the promontory, hence the anterior (right) parietal bone is deeper; L. O.: the sagittal suture is nearer the symphysis, hence the posterior (left) parietal bone is deeper; R. O.: the lesser fontanel is deeper and hence the presenting part the chin approaches the breast); S. O.: the sagittal suture is in the first oblique diameter of the pelvic inlet (Figs. 21, 22, 24, and 28 in the text).

The woman at this time may still be allowed to be up.

With the further descent of the head into the true pelvis, the *first rotation* of the head about its transverse

Lith. Reichhold, München

Reichhold München

axis takes place:[1] descent of the lesser fontanel (Fig. 4) the result of pressure of the fetal vertebral column.

The entrance into the plane of pelvic contraction is followed by the *second rotation* of the head, or rotation about its small oblique diameter; the lesser fontanel moves forward (Plates 3 and 4, Fig. 5). This is owing to the increase in the anteroposterior diameter of the small pelvis as the exit is approached, and to the increased resistance offered by the spines of the ischium which project into the lumen of the pelvis. The greatest circumference of the head is now in the external os, so that the amniotic sac projects into the vagina (Fig. 4). The woman, especially if she is a multipara, must now go to

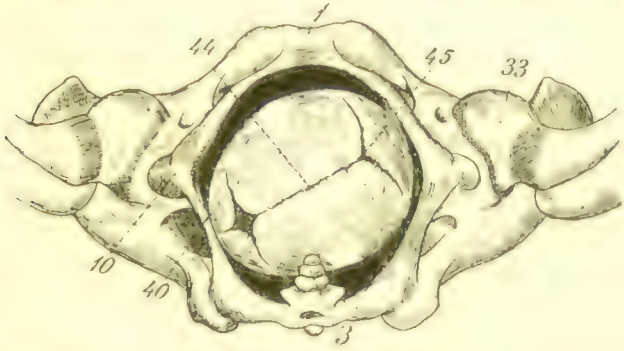

FIG. 1.—Vertex presentation I. Sagittal suture in the first oblique diameter of the plane of pelvic contraction.

bed; usually she assumes the dorsal position. End of the dilatation-stage, pains diminish; the abdominal pressure is now called into action. The woman becomes red in the face and perspires; characteristic groans are emitted.

Palpation, when the head has entered the plane of pelvic contraction (first and second rotation of the head) (Fig. 1 in the text), reveals: The amniotic sac is low down in the vagina or ruptures when the os is distended to 2–2¾ in. (5–7 cm.). The head immediately plugs the os, thus

[1] The head performs three movements during labor: (1) Descent, (2) Rotation, (3) Flexion.

Plate 5.

Vertex Position I. in the Expulsive Stage after Rupture of the Membranes (sagittal section through the trunk). The fundus of the longitudinally distended uterus is closely applied to the breech of the fetus, which is also in a position of extension. The head has rotated almost into the conjugate of the plane of pelvic contraction, and is beginning to distend the perineum. The back is on the left side and in front (Position I.); the entire trunk is still within the uterus.

preventing the escape of the amniotic fluid; it coincides with the interspinal line.

Now begin the rotations (onset of the expulsive period): The lesser fontanel has descended and can be palpated more to the left and in front (Figs. 1 and 3 in the text): the sagittal suture is in the first or right diagonal of the

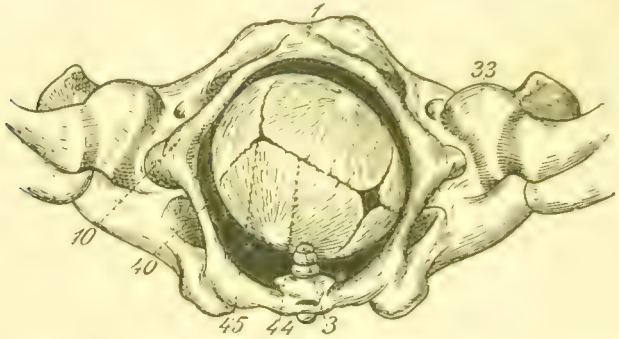

FIG. 2.—Vertex presentation II. Sagittal suture in the second oblique diameter of the plane of pelvic contraction.

pelvis (from the right sacroiliac articulation to the left iliopubic tubercle).

At the pelvic outlet the head, which is now within the vagina, completes the internal rotations (I. and II.), and, appearing at the pelvic outlet, begins to distend the vulva (Plates 5 and 6, Figs. 5, 6, 7). Return of the labor-pains (*dolores conquassantes*, from pressure on the sacral plexus); desire to defecate, owing to the contraction of the levatores ani by the pressure on the perineal muscles. The sagittal suture is in the anteroposterior diameter (Fig. 4 in the text).

Anst. F. Reichhold, München

Palpation, when the head has entered the pelvic outlet (Fig. 5), shows the lesser fontanel to be behind the symphysis; the sagittal suture in the conjugate; the vulva gapes, the perineal and rectal regions bulge (Plates

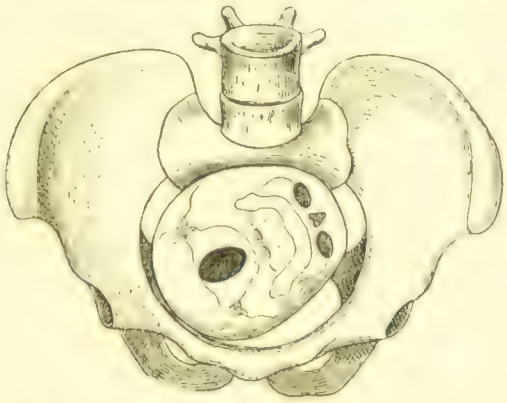

FIG. 3. Vertex presentation I. seen from above. The position corresponds to Fig. 2.

5 and 6, Fig. 7). The perineum should be protected (Figs. 9 to 11).

The **third rotation**,—around the transverse axis of the head, the chin receding from the breast (Figs. 6 and 8),—takes place as the head escapes; the neck catches on the symphysis, the occiput is rotated around it, and the head is brought into extension by the resistance encountered on the pelvic floor. The head escapes in its suboccipitobregmatic circumference ($12\frac{5}{8}$ in. 32 cm.) (Plates 6 and 7).

The woman should now be placed on her left side.

Appearance during the protection of the perineum (Fig. 9): A hairy portion of the head, the occiput, first appears in the vulva. With the right thumb and forefinger we protect the frenulum by drawing together the tissues on either side of the labia, while the thumb of the other hand is applied to the perineum and forces the head against and around the symphysis. If, in spite of

Plate 6.

Vertex Position I. at the Moment when the Head has entered the Vulva, after a vigorous Labor-pain (sagittal section through the trunk). —The perineum is greatly distended and bulges forward; the occiput appears in the vulva. The contracting fundus of the uterus ascends over the fetal trunk along its back, and forces the trunk and breech into the lower uterine segment; the thickened fundus is applied to the child like a cap and contains only the extremities and amniotic fluid.

all our efforts to prevent it, the frenulum becomes bloodless from the tension, it should be split by a single lateral incision carried as deep as may be required (if necessary,

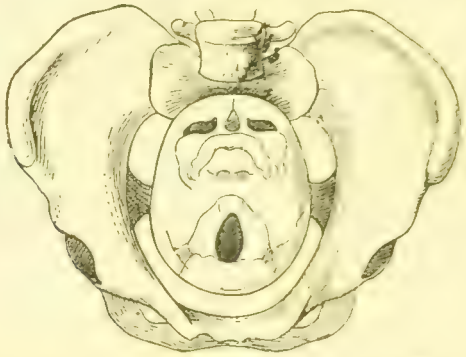

FIG. 4.—Vertex presentation I. Anteroposterior diameter of the head in the conjugate of the pelvic outlet. (To avoid confusion, the head is shown in a relatively higher position with reference to the true pelvis.)

through the fascia and into the constrictor vaginæ), using Cowper's scissors or a protected episiotomy knife. The woman should be forbidden to strain. Incidentally it may be noted that episiotomy wounds often heal less kindly than slight perineal tears, which, after all, the former do not always prevent.

During the pain the head should be held back with the other (left) hand until the larger fontanel is born. The advance of the head during this critical time can be regulated by pressure between labor-pains. The perineum should be stripped back during the pauses between pains, so that the lesser fontanel, brow, nose, and chin appear in the order given. The face turns toward the right

Lith. Anst. F. Reichhold. München

maternal thigh. The caput succedaneum is on the right parietal bone (Figs. 12, 13).

In so-called "over-rotation," the lesser fontanel appears at the last moment under the right ramus of the pubis, so that the face turns toward the left thigh and a little more posteriorly. The shoulders then escape as in cranial position II. Over-rotation not infrequently begins in the earlier stages of labor (see Plate 3).

To assist the delivery of the face, three manipulations are requisite, the first of which at the same time serves to protect the perineum and forces the brow and face against the symphysis and over the perineum. These manipulations are:

(*a*) Ritgen-Fehling's manipulation: The hand is pressed against the sacrum from without (Fig. 10).

(*b*) Smellie-Ritgen's manipulation: The index finger, or the index and second fingers, are introduced into the rectum and passing over the face exert pressure on the chin (Fig. 11).

(*c*) Hohl's manipulation: The fingers obtain a hold in the greater fontanel, and the head is drawn around the symphysis.

In the *delivery of the trunk* the anterior shoulder first appears under the symphysis, whereupon the posterior shoulder glides over the perineum and is immediately followed by the trunk. The entire trunk escapes from the body of the uterus at the same time as the head begins to impinge on the perineum (Plates 6 and 7). The uterus is then so closely applied to the fetal trunk that the latter is extended; the contraction-ring ascends along the fetal back so that the breech finally glides down on the side (left) immediately under the round ligament and enters the lower uterine segment. The uterine body then contains only the lower extremities, the amniotic fluid, and the ventral surface of the fetus (Plate 7).

It happens even more frequently than the above-described over-rotation that the head is born in the normal way, but the shoulders pass in the opposite oblique diameter, so that the left shoulder appears under the symphysis.

Method of Assisting the Birth of the Trunk (Fig. 13).—As soon as the head is born, the umbilical cord must be felt for, and, if necessary, loosened from the neck (Fig. 12); that is to say, if it is coiled around the head and shoulders, it must be pushed back.

Plate 7.

Vertex Position I. when the Head enters the Vulva, during a vigorous Labor-pain. Palpation shows that the fundus is firmly contracted and reaches to the right costal margin, being closely applied to the fetal trunk, as shown on Plate 6. The fetal trunk, including the breech, occupies the lower uterine segment and the vagina, leaving only the extremities, amniotic fluid, umbilical cord, and placenta in the fundus. The contraction-ring is found below the umbilicus, running obliquely from left to right and from above down. The left round ligament is in front of the fetal trunk.

The subsequent escape of the trunk is assisted by pressure on the fundus uteri and fetal trunk through the abdominal walls, after Kristeller (Fig. 13). The birth of the shoulders may be assisted by slight traction on, and depression of the head, or by hooking the index finger into whichever axilla is most easily reached (usually the posterior), going in on the dorsal surface (Fig. 110). After the posterior shoulder (the left in L. O. A.) has passed the perineum, the head is depressed and the anterior shoulder is drawn up under the symphysis with or without traction in the axilla; if the posterior shoulder is born first, the head must be elevated.

After the child is born and the eyes have been cleansed, or one to two drops of a two-per-cent. silver-nitrate solution have been instilled, the umbilical cord is tied with two ligatures at a distance of two to three fingers' breadth from the umbilicus (Fig. 14), and divided between the ligatures. The second ligature, which is placed close to the vulva, serves to indicate the descent of the placenta, and at the same time keeps it full of blood and thus excites the uterus to more energetic contractions. It also guards against hemorrhage in the case of twins.

Duration of the dilatation-stage: In primiparæ, 12 to 20 hours; in multiparæ, 1 to 12 hours. Duration of the *expulsive stage:* In primiparæ, 1½ to 7½ hours; in multiparæ, ½ to 1½ hours. Duration of the third stage of labor: From ½ to 14 hours; on an average, 2 to 2½ hours.

The *placenta* is usually expelled (Figs. 15 and 16) by the uterine contractions during the first half-hour; the central portion and a part of the marginal portion of the placenta serotina

are first loosened from the uterine wall. This is followed by the formation of a retroplacental hematoma, and thus the ovum is propelled *in situ* to the internal os, and thence, after total separation of the placenta, with its entire fetal surface, into the vagina. The membranes retract around the more massive decidua serotina which lies toward the fundus, and the fetal surface of the amniotic sac is delivered first (Fig. 16). The placenta is finally expelled from the lower uterine segment by the abdominal pressure. The membranes and the placenta must be carefully examined to make sure that nothing has remained behind. The retroplacental hematoma contains on an average 225 gm. of blood. (For further details compare *Atlas of Obstetric Diagnosis and Treatment*, second edition.

In *Duncan's mode of separation* (Fig. 17), which occurs more rarely, the retroplacental hematoma forms about the margin of the decidua serotina instead of at the center, so that one margin of the maternal surface of the placenta descends and the membranes come away at the same time, either to one side, or above and behind the placenta, and do not surround the maternal surface (Fig. 17).

If the placenta is not expelled from the lower uterine

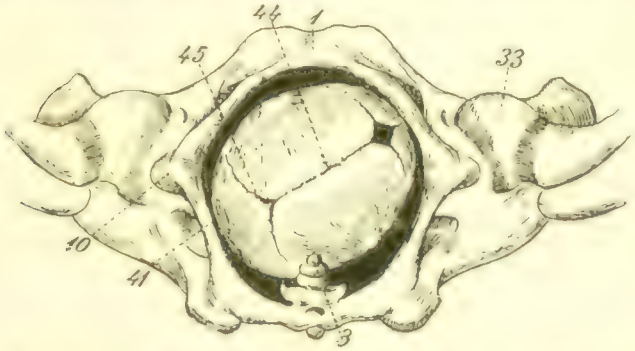

FIG. 5.—Presentation II of the sinciput. Sagittal suture in the first oblique diameter of the plane of pelvic contraction.

segment, it must be expressed by Credé's method during a labor-pain (Fig. 18), *without rubbing*.

In the case of an adherent placenta in atony of the uterus, or in retention due to circular stricture with hemorrhages and only partial separation, the placenta must be extracted with the hand. This should not be done until at least two hours have elapsed, unless there is an

urgent indication (Fig. 19). Premature massage and attempts at expression only interfere with the mechanism of contraction and with the separation and expulsion of the placenta.

The mechanism of labor in the second vertex position (vertex presentation) (Figs. 24 and 2 in the text) is analogous to the one just described, with the difference that the back and lesser fontanel are on the right side. This second position (II.) is more apt to be converted into the third; that is to say, presentation of the sinciput, back on the right side (see Fig. 5 in the text), because in position II. the vertex constantly tends to rotate backward.

§ 2. **Sinciput Positions (presentation of anterior fontanel, vertex positions III. and IV.). Mechanism I. with the Chin Flexed on the Breast** (Figs. 25 and 26).

In the first sinciput position (I.) the back[1] is on the left, the extremities are on the right side. The heart-sounds are heard on the left side, midway between the umbilicus and the anterior superior spine; in other words, the sinciput position is not a separate position like that of the vertex, but rather a subvariety of vertex presentations I. or II. In rarer cases, as for instance in lumbosacrokyphotic pelves, the back may be posterior: the sinciput position in that case is completed before the head engages in the superior strait.

Causes of Mechanism I.—Abnormally diminished resistance; large pelvis or diminished size of the fetus.

Palpation when the head engages at the superior strait in sinciput position I. (Fig. 25) shows the sagittal suture in the transverse diameter of the pelvis, the lesser fontanel, etc., as in vertex position I. More rarely the sagittal suture is already in the oblique diameter: the greater fontanel to the right and in front.

The *first* rotation, about the transverse axis, with approximation of the chin toward the breast, regularly takes place (Fig. 26); but owing to the diminished

[1] Kehrer calls this the second (II.) because it is the rarer.

resistance at the plane of pelvic contraction, either on the part of the pelvis or of the fetal head, the latter either becomes arrested in the transverse diameter—deep transverse position—or the lesser fontanel rotates backward at the level of the spines, and the greater fontanel is brought forward (Fig. 6 in the text). As in vertex

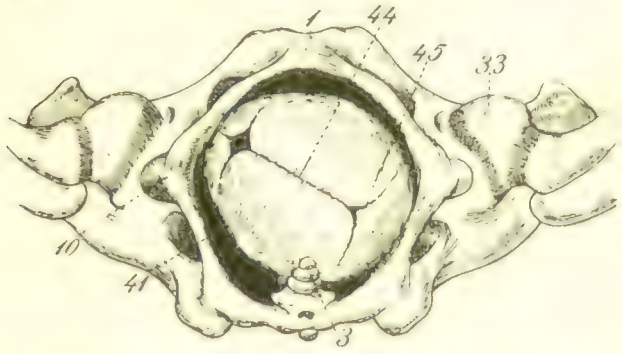

FIG. 6.—Sinciput position I. Sagittal suture in the second oblique diameter of the plane of pelvic contraction.

presentation I., the chin remains flexed on the breast during this *second* rotation about the vertical diameter of the head.

Palpation when the head enters the plane of pelvic contraction (Fig. 6 in the text; first and second rotations of the head) shows the lesser fontanel low and to the left and rotating backward, the greater fontanel to the right and more in front; the sagittal suture rotates into the second or left oblique diameter.

The *internal rotation* as just described is completed at the outlet. The perineum is more apt to be torn because the dilation of the vulva is effected by the broad occiput.

Palpation when the head enters the outlet (Fig. 26) shows the greater fontanel behind the symphysis, the lesser fontanel low in the pelvis, but turned toward the perineum.

The *third* rotation (about the transverse axis) is effected by the greater fontanel coming against the symphysis

(Fig. 26). The occiput passes over the perineum, the sinciput appears under the symphysis. The head passes in the suboccipitobregmatic periphery 12½ in. (32 cm.).

During the protection of the perineum nothing but the hairy scalp is seen as the head comes through. The caput succedaneum is found at the superior anterior corner of the right parietal bone.

The shoulders emerge in the first or right oblique diameter; that is to say, in the diameter opposite to that in which the sagittal suture passes.

In the *second* sinciput position, which is more frequent than the *first*, the mechanism is the same, except that the back is felt on the right side, and the greater fontanel on the left. The caput succedaneum is on the left parietal bone, in the same relative position as in the *first* sinciput position (Fig. 5 in the text).

For mechanism II., see Group III. (Figs. 27 and 28).

Treatment.—Applying the general principle of putting the woman on the side which contains the fetal portion that it is desired to have below and in front (vertex presentation I. on the left; face presentation I. on the right), the woman in sinciput position II., for instance, is placed on her right side, because under favorable conditions the lesser fontanel, even at the pelvic outlet, rotates from behind forward on the right side and thus converts the position into vertex position II. If we fail in this attempt, we select the greater fontanel for the presenting part and then place the woman on her left side.

In case of complications, forceps are indicated (Figs. 112 to 114); if the fetus is dead, craniotomy. In extraction of the fetus, the greater fontanel is in front. If the brow has descended and impinges on the anterior wall of the pelvis in the diagonal of the plane of pelvic contraction, the fetal skull should be rotated as in the Figure 7 operation, given on page 31.

CHAPTER II.

FACE PRESENTATION, CHIN ANTERIOR

(Figs. 34–39; Fig. 77 in the text).

Face positions are also longitudinal presentations, and, strictly speaking, are nothing but anomalies in attitude developing during labor. Like sinciput and brow presentations, they are produced by deflection from vertex positions; but as there is always a much more decided and more constant alteration in the position of the trunk, because the occiput is wedged in from the side (compare Fig. 35 with Fig. 34), it is best to retain the customary name of face presentation.

The chin and face are in extreme extension, the verte-

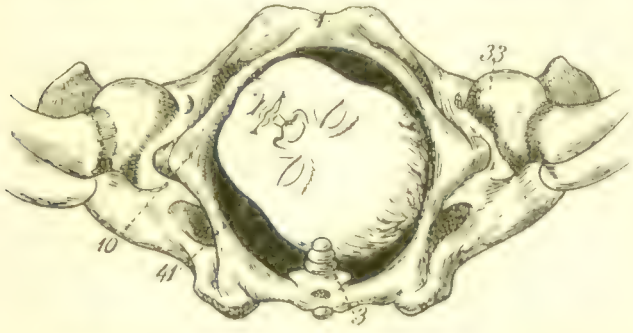

FIG. 7.—First face position, chin to the right and in front. R. M. A. The vertical axis of the face is in the second oblique diameter of the plane of contraction.

bral column is excessively flexed at the nape of the neck, so that the face presents.

The back occupies an oblique position from above downward, the breast and smaller parts being closely applied to the anterior uterine wall, so that the heart-sounds reach the ear directly from the fetal breast.

A face presentation with the chin anterior frequently constitutes a dystocia.

§ 3. **Mechanism in the First and Second Face Positions, Chin Anterior.**

Cause.—Usually the combination of contracted pelvis, excessively large fetus, and pendulous abdomen.

In the first face position, external examination gives the following result: The back runs obliquely from above downward and from left to right; extremities to the right; heart-sounds heard to the right, below the navel. The occiput causes the uterine wall to bulge to the left of the symphysis. On *palpation* in the first face position, chin anterior, when the head has entered the pelvic inlet, nothing can be felt in the fornix long after labor has begun; finally, the face is felt lying crosswise above the pelvic inlet, chin to the right, brow to the left, the right half of the face presenting (Fig. 34).

In the *first* rotation, about the transverse axis of the head, the chin descends (Fig. 36); in the *second* rotation of the head, the chin moves toward the symphysis (Figs. 35, 36).

Cause.—The resistance encountered by the longer arm of the lever of the occiput.

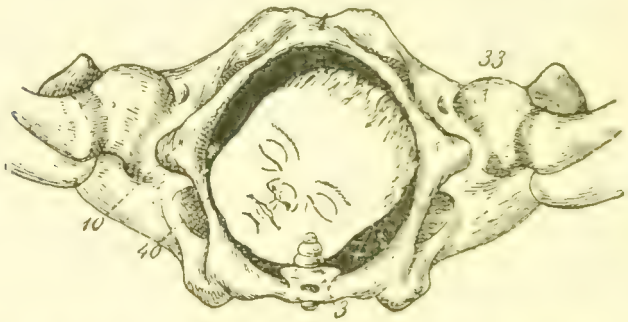

FIG. 8.—First face position, chin posterior and to the right. Vertical axis of the face in the first oblique diameter of the plane of pelvic contraction.

Palpation, when the head engages in the plane of pelvic contraction (first and second rotations) (Fig. 7 in the text),

shows the head to be more easily palpated; chin lower, at first to the right, then behind the right ramus of the pubis; vertical axis of the face in the second or left oblique diameter. The mouth is recognized by the tongue and by its size. The parietal eminence can be felt at or below the iliopectineal line; the head is not movable. (Caution is necessary in making the vaginal examination.)

At the pelvic outlet, the third rotation about the transverse axis takes place; the chin approaches the breast in front of the pubic arch, and the brow and occiput appear over the perineum. The throat therefore comes against the symphysis (Figs. 37 and 38). The submentofrontal periphery (12⅝ in. = 32 cm.) is the first to pass; the submento-occipital or greater circumference (14⅜ in. = 36.5 cm.) the last. During the protection of the perineum, the chin appears below the symphysis and glides upward along the anterior surface, the brow passing over the perineum. Great care is necessary because the greatest periphery of the head passes through the vulva (Figs. 37 and 38).

The face is turned toward the mother's right thigh as in vertex presentation I., owing to the fourth rotation about the long axis of the fetal body, which takes place during the passage of the shoulders (Fig. 39). The trunk is rotated about its sagittal axis and follows the curvature of the pelvis. The right side of the face is swollen and very dark in color, especially near the corner of the mouth. The shape of the skull in face presentations is characteristic (Fig. 42).

The mechanism in the second face position, which is relatively more frequent than the first, is analogous to that of the first; the heart-sounds are heard to the left, below the umbilicus; chin to the left.

For face presentation with chin posterior, see Group III.

Prognosis.—The labor is often normal, but there is danger of overstretching and bruising of the maternal soft parts (urogenital fistula), and the perineum is easily torn. It is more dangerous for the child, owing to the excessive extension of the vertebral column and the pressure on the jugular veins, which may cause cerebral apoplexy.

Treatment.—Similar to that of sinciput positions.

CHAPTER III.

BREECH POSITIONS

(Plate 8, Figs. 59 to 74, and Fig. 9 in the text).

These are longitudinal positions with presentation of the pelvic extremity (breech, breech and heel, complete and incomplete footling, and knee presentations). The head occupies one side of the fundus and is flexed on the breast, the smaller parts are found lower down than in cranial positions, and the heart-sounds are heard at or above the umbilicus. The breech remains above the pelvic inlet until the onset of labor, even in primiparæ.

Cause.—Diminished size of the fetus, leading to immature and premature births, twins, hydramnion, deformities, maceration, defective development of the lower uterine segment, atony of the uterus.

§ 4. Mechanism of Breech Positions I. and II.

By *external examination* in breech position I. (Plate 8, Fig. 59) the head is found in the right half of the fundus, the back to the left and in front; the heart-sounds are heard in the median line, at or slightly above the umbilicus.

Palpation in breech position I., when the breech enters the pelvic inlet (Fig. 9 in the text), shows the anus and the intergluteal fissure in the transverse or in the first

oblique diameter and nearly at the center of the pelvic inlet. (The anus is the most reliable diagnostic sign; it is smaller than the mouth, and the characteristic contraction of the sphincter muscle is felt—it "bites." The examining finger may be stained with meconium.) The tip of the coccyx is felt to the right of the anus, with the genitalia to the left; later these parts are more difficult to recognize on account of the swelling; the transverse diameter of the fetal pelvis is in the second oblique diameter of the maternal pelvis. The left buttock presents, being directed to the right and forward (Fig. 60).

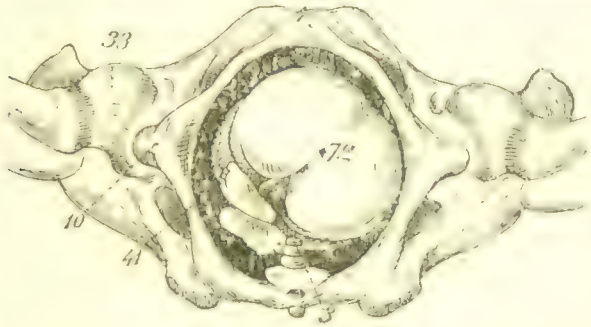

FIG. 9.—Breech and heel presentation. Fold of the nates in the first oblique diameter of the plane of pelvic contraction.

As the breech enters the pelvis the *first rotation*, about the anteroposterior axis of the fetal pelvis, takes place and the presenting hip descends (Plate 8, Fig. 61). During the *second rotation*, about the longitudinal axis of the fetal trunk, the same hip rotates into the anteroposterior diameter behind the symphysis and descends still lower (Fig. 62).

Palpation, when the breech enters the plane of contraction (first and second rotation), shows the presenting left buttock at first on the right-hand side and in front, then it passes behind the symphysis, being always lower than the posterior buttock.

At the pelvic outlet the *third rotation*, about the antero-

Plate 8.

Breech Position I. (L. S. A.) at the End of Pregnancy, in a Primipara (Waldeyer.). The cervical canal is not dilated, the breech is above the pelvic inlet. As a rule, the anterior buttock is the first to engage; the deeper position of the posterior buttock is only apparent because the entire fetus is pushed against the symphysis, owing to a fracture of a sacral vertebra. The uterus is relaxed and adapts itself to the contours of the fetus and of neighboring organs. There is no bulging of the amniotic sac above the internal os. The back is turned to one side (to the left in the first position); the extremities, as well as the entire vertebral column and the nape of the neck, are flexed.

posterior diameter of the fetal pelvis, takes place; the right—that is to say, the posterior—hip descends and passes over the perineum, the left hip being arrested by the symphysis (Fig. 63).

Appearances during the protection of the perineum: The left presenting buttock is arrested by the symphysis; the right passes over the perineum, after which the left emerges below the symphysis; the trunk descends in the axis of the pelvic canal and the posterior leg appears, followed immediately by the anterior leg, either in flexion (see Fig. 59) as in the normal position of the fetus in utero, or they are flexed as the breech emerges and assume an abnormal attitude in close apposition to the trunk (Figs. 60 and 61), in a position which is rarely assumed in pregnancy. The left buttock and the genitalia are swollen.

Owing to the danger of pressure on the cord, labor should now be speedily terminated, although up to this point inaction is indicated, as otherwise the arms may be elevated or the head may be extended and a greater periphery pass.

The arms are flexed on the breast, the elbows are the first to appear (Fig. 63); first the anterior or left, and then the posterior. The posterior right shoulder is usually the first to pass over the perineum. By a *fourth rotation*,—about the longitudinal diameter of the trunk,—the head, which engages in the transverse diameter, rotates until its anteroposterior diameter coincides with

the conjugate. The occiput is in front and catches on the symphysis, so that the face passes over the perineum owing to the *fifth rotation*,—about the transverse axis of the head. The perineum should be protected (Figs. 65 and 66). Finally the occiput appears under the symphysis (Fig. 66).

Prognosis.—Usually favorable for the mother. For the child, breech presentations may not be unfavorable, while the footling (especially complete footling) presentation usually is (§ 17).

Treatment.—As soon as the breech is born, labor should be terminated by means of Kristeller's manipulation mentioned in § 1 (Fig. 110), the delivery of the trunk and head being assisted by abdominal pressure. If this fails, the legs should be delivered as shown in Figs. 67–71, the trunk and arms extracted (see Manual Extraction, § 27, and the conversion of a breech presentation into a complete footling presentation, § 20).

The head may then be extracted by Veit-Smellie's (or more correctly Mauriceau-Lachapelle's) method (Fig. 73). The shoulders are seized with the index and fourth fingers of the left hand, the third finger being pressed firmly against the occiput, and direct traction downward is made. At the same time the right index finger is inserted into the mouth and pulls on the lower jaw, the thumb being placed exactly opposite the index finger against the lower border of the jaw, so as to avoid fracture or luxation. The methods of Wigand, A. Martin, v. Winckel (Fig. 72) may also be employed. In the latter method the left hand performs the same movement as the right hand in the above-described method, while the right hand is utilized to express the head by pressure on the fundus. If these attempts all fail, pressure may be applied to the fundus with both hands, and after that nothing is left but forced traction with both hands on the shoulders (Fritsch) or craniotomy, as such resistance can be offered only by an abnormal skull or by an excessive contraction of the pelvis. The use of the forceps for the delivery of the aftercoming head is not likely to prove successful after the above-described methods have failed, except possibly in the case of a moderately contracted funnel-shaped pelvis (distance between the tuberosities

[1] The Pragué method has been shown by Ahlfeld and v. Winckel to be too dangerous (laceration of the cervical vertebral column) and should never be used.

of the ischium at least 3½ in. (8 cm.) without any marked shortening of the conjugate at the outlet).

It is evident that Wigand's, Martin's, or v. Winckel's method is most suitable when the head is higher, and that of Veit and Smellie after it has descended. As a rule, the index finger that lies most conveniently to the face is inserted into the mouth. The Vienna method after Braun (see Fig. 94) is the least injurious of all, but hardly effective enough.

Note.—If the attempt to deliver the head by traction or pressure should fail, the conjugate may be enlarged by allowing the legs to hang down in the so-called Walcher's position.

§ 5.—Table I.

	Descent of:	*Arrest of:*	*Caput succedaneum in first position:*
Vertex presentation:	lesser fontanel;	nape of neck;	right parietal.
Sinciput positions:	I. greater fontanel II. brow; greater fontanel	I. greater fontanel II. brow	greater fontanel and immediate surroundings on the right.
Brow presentation:	brow;	upper jaw;	right frontal.
Face presentation:	chin;	neck;	right half of face about the angle of the mouth.
Breech position:	anterior hip;	anterior hip;	left buttock.

Table II.—Shape of the Skull.

Vertex position I.: The head is drawn out toward the vertex: the posterior left parietal bone is pushed forward and under the anterior right; the right parietal bone therefore presents and is the seat of the caput succedaneum (Fig. 14).

Sinciput position: Head rather spheric: the sinciput is rounded off.

First or Naegele's presentation of anterior parietal bone: The posterior left parietal bone is flattened, depressed, and pushed under the adjacent bones; the anterior right parietal bone bulges forward on account of the caput succedaneum (Plate 60 in Atlas II., second edition).

First or Litzmann's presentation of posterior parietal bone: The anterior right parietal flattened; the left bulges.

First or Roederer's presentation of the occiput: Head shaped like a pyramid, the apex corresponding with the lesser fontanel.

Face presentation: Extreme dolichocephalus (Fig. 42).

Brow presentation: Head shaped like a pyramid; the brow forms the apex, the submento-occipital periphery the base (Fig. 33).

Breech positions: Spheric (Figs. 65, 66).

TABLE III.

In cranial position I.:	*Clinical course and behavior of the soft parts.*	*Obstetrical course.*
Period of dilatation (first stage).	Onset of labor: Dilatation of the internal os; the cone of the membranes begins to form; true labor-pains (uterus is hard).	In multiparæ, head enters true pelvis (in primiparæ, it has already entered). Sagittal suture in the transverse diameter; occiput descends (it is on the left), back turned forward and to one side.
	External os completely dilated; membranes usually ruptured.	Head in interspinal line, in the oblique diameter (lesser fontanel to the left and in front), deep in the pelvis (frontal eminences can be felt at or below the iliopectineal line; in face presentations, the parietal eminences). The head is fixed.
Period of expulsion (second stage).	Head in vagina; abdominal pressure (bearing down);	Head rotates in the pelvic outlet, with the sagittal suture in the conjugate.
	Bulging of the perineum;	(Lesser fontanel behind the symphysis).
	Under expulsive pains engagement occurs and then delivery, occiput passes under the symphysis, then the face over the perineum;	Occiput rotates about the symphysis, the nucha impinges, the coccyx is pressed backward.

GROUP II.

Presentations Resulting from Deformities of the Pelvis or Certain Other Typical Conditions which may be specially Favorable, or at least not Unfavorable, for such Conditions.

CHAPTER I.

THE OBLIQUITIES OF THE CRANIAL POSITIONS.[1]

These consist principally in asymmetric positions of the presenting head at the inlet, caused by pelvic deformities. They may occur in a normal labor if the

[1] See also § 23, C. b, under Indications.

head fails to become sufficiently fixed at the pelvic inlet. Under normal conditions the position of the head at the pelvic inlet is such that the sagittal suture lies either in the transverse or in the oblique diameter and approximately equidistant from the promontory and from the symphysis; the greater and lesser fontanels are at the same level, or, in other words, enter the pelvis at about the same time.

§ 6. **Solayrès' Obliquity.**—The sagittal suture lies in the oblique diameter of the pelvic inlet (Fig. 24).

It is due to the deviation from the promontory of the head before it has come into close relation with the pelvic inlet, and occurs particularly when the trunk is rotated either by the uterine contractions or by movements on the part of the woman.

Occasionally the sagittal suture is observed to rotate into the conjugate immediately after the engagement of the head.

The causes are generally contracted pelves (combination with presentation of the occipital bone) and lumbosacrokyphotic funnel-shaped pelves with elliptical inlet, the longest diameter being anteroposterior; in a pelvis of this kind, such a presentation appears *a priori* to be the natural one.

§ 7. **Naegele's Obliquity.**—Presentation of the anterior parietal bone (Figs. 21 and 10 in the text). The posterior parietal bone slips upward along the promontory: the sagittal suture approaches the latter structure, and the anterior parietal bone enters the pelvis. Accordingly the posterior parietal bone is found to be flattened after birth and sometimes even depressed or fractured (compare *Atlas of Obstetric Diagnosis and Treatment*, second edition, Figs. 130–132), and pushed beneath the anterior parietal bone, which bulges forward. The sinciput is usually deeper than the occiput.

Causes.—Pendulous abdomen, shortened conjugate, and lateral flexion of the fetal trunk, so that the axis of the uterus and of the fetal trunk is not perpendicular to

the pelvic inlet, the head being displaced toward the lumbar vertebræ.

The highest grade of this deviation is called "pres-

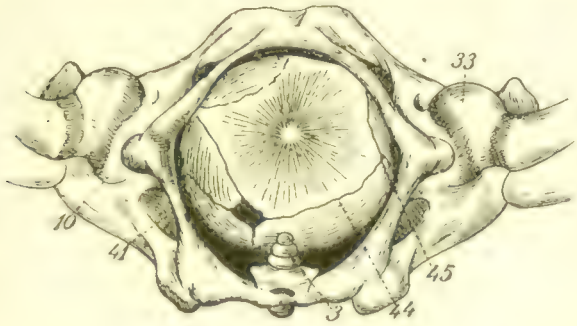

FIG. 10.—Naegele's obliquity. Presentation of the anterior parietal bone; the sagittal suture approaches the sacrum.

entation of the anterior ear," and is very unfavorable in contracted pelves (compare § 16).

Palpation (Fig. 10 in the text) in the first dorsal position, with presentation of the anterior parietal bone and

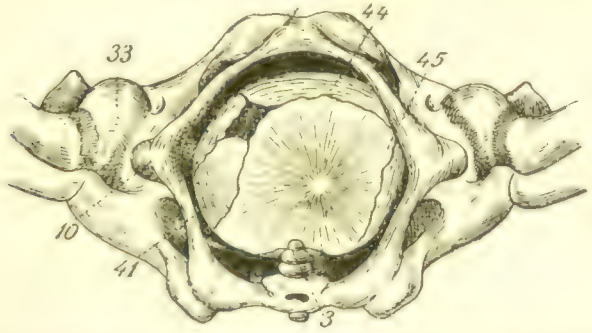

FIG. 11.—Litzmann's obliquity. Presentation of the posterior parietal bone; the sagittal suture approaches the symphysis.

deep position of the sinciput, shows the sagittal suture near the promontory, the lesser fontanel high and to the left, the greater fontanel low and to the right; the right

Plate 9.

Second Presentation of the Posterior Parietal Bone, with Descent of the Greater Fontanel, in Flat Rhachitic Pelves, complicated by Prolapse of the Posterior Hand (sagittal section through the trunk). In order that the head may pass the antero-posteriorly contracted pelvic inlet, the smallest (that is to say, the bitemporal) diameter enters first, and the sinciput and greater fontanel descend so that one lateral half only engages in the pelvis; in other words, one of the parietal bones, usually the anterior one. This is known as Naegele's obliquity. In the figure before us, evidently owing to the prolapse of the right arm, the posterior parietal bone has entered first, producing the so-called Litzmann's obliquity or presentation of the posterior parietal bone. Prolapse of an extremity or of the umbilical cord is particularly apt to occur in flat pelves, because of the marked prominence of the promontory which arrests the head, and the recession of the sacral ala which permits a large portion of the amniotic fluid to descend into the anterior pole of the sac and thus affords the smaller parts an opportunity of slipping past the head. Until the rupture of the membranes, we speak of presentation of one of the smaller parts; after the membranes have ruptured, the condition becomes a prolapse. Prolapse of one of the extremities is apt to produce a lateral or other extramedian deviation of the large presenting part (the head).

parietal bone presents. In this abnormal attitude the head descends to the pelvic floor, where it executes the usual rotations.

Prognosis.—Favorable in milder grades of pelvic contraction. If the general conditions (pelvis, shape of the uterus, etc.) are normal, it occurs as a transient condition in one-third of all cases.

Treatment.—Abdominal binder to support the pendulous abdomen and correct the anteversion (see also § 8).

§ 8. **Litzmann's Obliquity.**—Presentation of the posterior parietal bone (Figs. 22, and 11 in the text): The sagittal suture approaches the symphysis; the posterior parietal bone enters the pelvis. The sinciput is occasionally lower than the occiput (Plate 9).

Causes.—Pelvic contraction, usually of the conjugate, and lateral flexion of the fetal spine at the level of the cervical vertebræ or of the uterine axis, combined with displacement toward the posterior abdominal wall when

Lith. Anst. F. Reichhold, München

the woman lies on her side and the abdominal walls are relaxed. It may occur in normal pelves.

The highest grade of this anomaly is designated as presentation of the posterior ear; it is extremely unfavorable in contracted pelves.

Palpation (Fig. 11 in the text) in the first dorsal position shows the sagittal suture close to the symphysis; the lesser fontanel to the left, the greater fontanel to the right; the posterior (left) parietal bone presents.

The anterior parietal bone slips down behind the symphysis until the posterior half of the head has descended into the hollow of the sacrum.

Prognosis.—Favorable if there is no contraction. It may be observed as a temporary condition at the beginning of labor in about one-third of all normal births, especially in primiparæ. It is also favorable if the conjugate is only slightly shortened. It is quite unfavorable even in moderate grades of pelvic contraction and whenever the sinciput descends, especially in generally equally contracted rhachitic pelves.

Treatment.—This depends on the degree of pelvic contraction (see *Atlas of Obstetric Diagnosis and Treatment*, second edition, Chap. VI.):

(1) If the head is high up and still movable, the child is alive and the true conjugate from $2\frac{3}{4}$ to $3\frac{1}{2}$ in. (7 to 8 cm.): version.

(2) If the head has engaged in the pelvis and is immovable, the child is alive, and the true conjugate between $2\frac{3}{4}$ and $3\frac{1}{2}$ in. (7 to 8 cm.): forceps. If the child is dead, perforation and craniotomy.

(3) If the true conjugate is $2\frac{1}{4}$ to $2\frac{3}{4}$ in. (5.5 to 7 cm.) in flat pelves or $2\frac{1}{2}$ to $2\frac{3}{4}$ in. (6.5 to 7 cm.) in generally contracted pelves: perforation or craniotomy. If the true conjugate is $2\frac{1}{2}$ to 3 in. (6 to 7.5 cm.), symphyseotomy. If the conjugate falls below $2\frac{1}{4}$ in. (5.5 cm.)—or in some cases $2\frac{1}{2}$ in. (6.5 cm.—even a mutilated child cannot be extracted[1] and a Cesarean section is indicated.

[1] These indications based on the size of the true conjugate are, of

§ 9. **Descent of the Greater Fontanel** (Plate 9, Fig. 27) (not to be confounded with presentation of the sinciput) may occur in any variety of cranial position and presentation, even in normal labors during the engagement of the head at the pelvic inlet. It occurs most frequently in flat pelves in connection with Naegele's presentation of the anterior parietal bone.

As the sagittal suture is pushed upward along the promontory and the larger biparietal diameter becomes arrested at the contracted conjugate, the narrower sincipital portion descends; that is to say, the small bitemporal diameter is able to pass the conjugate. This presentation is favorable in flat rhachitic pelves.

Causes. — Anteroposteriorly contracted pelves. In normal labors it occurs more frequently in the more spacious lower portion of the pelvis after the head has passed the contracted plane corresponding with the psoas.

Palpation (*second* sinciput position at the pelvic inlet, with descent of the greater fontanel) shows that the greater fontanel is easily felt to the left and in front; the lesser fontanel is high up to the right and behind.

The occiput follows late after the engagement of the sinciput; occasionally it descends into the true pelvis, with the sagittal suture in the transverse diameter.

Prognosis.—In itself favorable; it depends on the degree of anteroposterior contraction; it is unfavorable in generally contracted pelves.

Treatment.—See § 8.

§ 10. **Presentation of the Occipital Bone** (Roederer) (Fig. 23) occurs in generally equally contracted pelves when there is excessive flexion of the head and the occiput enters the pelvis perpendicularly. The posterior part of the head is pressed into a cone with the apex correspond-

course, modified by the strength of the labor-pains, the condition of the parturient canal, the size of the child, and all other accompanying factors. In rhachitic pelves, from ¾ to 1 in. (2 to 2.5 cm.) must be subtracted from the diagonal conjugate on account of the diminished obliquity of the symphysis. *First* grade of pelvic contraction, true conjugate 3¼ to 4 in. (8.5 to 10 cm.); *second* grade, 2⅞ to 3⅜ in. (7 to 8.5 cm.; *third* grade, 2½ to 2¾ in. (5.5 to 7 cm.).

ing to the occiput, so that the smallest (that is, the suboccipitobregmatic) periphery is able to pass. It is, therefore, an attempt on the part of nature to adapt the shape of the head to the abnormal shape of the pelvis. It is often combined with Solayrès' obliquity or an even greater rotation of the sagittal suture into the conjugate at the inlet; or it may occur in generally contracted flat rhachitic pelves with presentation of the posterior parietal bone.

Causes.—Generally equally contracted pelves, rigidity of the cervix and vagina. Sometimes it occurs as the head passes the contraction opposite the psoas.

Palpation (Fig. 23) in the second vertex position combined with Roederer's obliquity shows that the head has passed the pelvic inlet, the sagittal suture is in the second oblique diameter; the lesser fontanel is easily felt directed obliquely to the right and in front. The greater fontanel is felt with difficulty, if at all, high up to the left and behind.

Prognosis.—In itself it is a favorable presentation in equally contracted pelves. In high grades of pelvic contraction, paragomphosis or complete arrest of the head may occur and lead to early exhaustion of the labor-pains; or, in rare cases, to rupture. Pressure necroses are, however, quite common. Eclampsia is remarkably frequent, owing to the pressure on the ureters. Marked caput succedaneum.

In generally and anteroposteriorly contracted rhachitic pelves, it is relatively most favorable when combined with presentation of the posterior parietal bone; but rotation through the lesser oblique diameter (lesser fontanel anterior) occurs very late. Injuries of the parietal bone nearest the promontory are quite common (subcutaneous and subdural hematomata, fractures, and depressions).

Treatment.—If the true conjugate is over 3½ in. (9 cm.), the head should be pressed into the pelvic inlet during the last weeks of pregnancy several times a week, a number of minutes at a time (see *Atlas of Obstetric*

Diagnosis and Treatment, second edition, §§ 18 and 19. Other than that, the treatment is expectant. The woman should be delivered lying on the side which corresponds to the position of the occiput. In greater contractions of the conjugate, forceps (see § 7). Podalic version is applicable only in exceptional cases.

In generally and anteroposteriorly contracted pelves, forceps, if the condition is combined with presentation of the posterior parietal bone.

CHAPTER II.

DEEP POSITION OF THE HEAD IN THE TRANSVERSE DIAMETER IN VERTEX AND FACE PRESENTATIONS.

§ 11. In vertex positions the sagittal suture in such cases is found in the interspinal line, instead of in one of the diagonals; one-half of the head, therefore, has already passed into the pelvic cavity, and the two fontanels are at the same level. In face presentations, this is true also of the vertical line of the face.

Causes.—Presentations of the anterior parietal bone associated with an attempt on the part of the lesser fontanel to rotate forward in the true pelvis; the anteroposterior diameter of the head is unable at this level to pass the spines of the ischium. Flat pelves in which all the other diameters are usually normal, or even enlarged in the true pelvis. The sagittal suture, having passed the pelvic inlet in its largest (that is to say, transverse) diameter, encounters no further resistance, and therefore easily descends to the plane of pelvic outlet under the influence of vigorous labor-pains.

Prolapse of the anterior arm. Uterine inertia in presentations of the anterior fontanel. Funnel-shaped pelves if the sagittal suture has failed to enter the elliptical pelvic inlet in the line of the conjugate. An abnormally large pelvis or an abnormally small head.

Palpation shows the head to be low, with the sagittal

suture placed transversely, so that the interspinal line is obscured. The two fontanels are at the same level (Fig. 12 in the text).

Prognosis and Treatment.—The woman should be placed on the side corresponding to the lesser, or, if the labor has begun with presentation of the parietal bone,

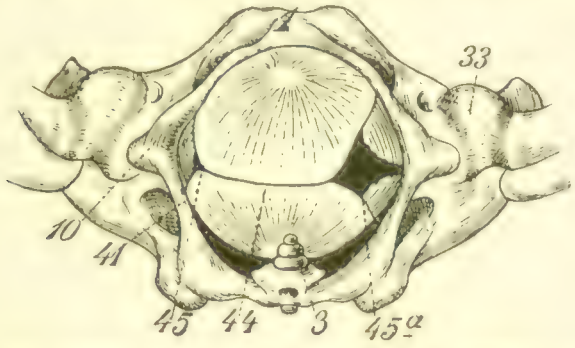

FIG. 12.—Deep position of the head in the pelvic cavity in vertex position II.

on that corresponding to the greater fontanel. If the head becomes arrested, forceps in the oblique diameter. Occasionally manipulation with one blade of the forceps may suffice.

If the head cannot be delivered in the vertex presentation, the forceps should be applied in the other oblique diameter and the head extracted in a presentation of the anterior fontanel.

CHAPTER III.

SPONTANEOUS EVOLUTION AND DELIVERY CONDUPLICATO CORPORE WHEN THE FETUS IS SMALL AND IN A TRANSVERSE POSITION.

§ 12. An immature fetus in transverse position may be born in one of three ways:

(1) By spontaneous version (Figs. 57 to 59) from a

transverse to a longitudinal—usually a breech—position.

(2) By spontaneous evolution (Figs. 55, 56). The head is arrested at the iliopectineal line, and the breech and trunk successively glide past the head and escape from the pelvis; in other words, version takes place in the true pelvis.

(3) Conduplicato corpore (Figs. 51 to 54). In shoulder presentations with prolapse of an arm, the head and trunk enter the pelvis together and pass through the parturient canal in that attitude.

Prognosis and Treatment.—In the case of an immature fetus or of a much macerated fetus, labor progresses without danger, and inaction is the best policy; gentle traction may be exerted on the prolapsed arm for the purpose of effecting a gradual dilatation of the soft parts.

GROUP III.

Positions and Presentations which in themselves produce Dystocia.

CHAPTER I.

DYSTOCIA IN DEVIATIONS OF THE HEAD IN HEAD PRESENTATIONS.

These abnormal attitudes, as a rule, do not develop until after the onset of labor, so that the name of the presentation refers usually to the mechanism at the pelvic outlet. This explains the frequent changes from presentation of the vertex to that of the sinciput, brow and face, and back again in the same order. Any one of these anomalies may be produced from any one of the others in the order given (compare Fig. 46 *et seq.*).

§ 13. **Presentation of the Sinciput.**—Mechanism of escape II. with the chin away from the breast (Figs. 27, 28; compare § 2).

Causes.—Abnormal resistance due to a contracted pelvis, or to a very large and unyielding head, or to tumors or other deformities, either of the parturient canal or of the fetus. In funnel-shaped pelves, the sinciput presents even at the pelvic inlet (see Chapter I., Vertex Presentations, foot-note, and § 2).

Palpation at the moment when the greatest periphery of the head has descended to the interspinal line shows low position of the greater fontanel in front and to one side of the symphysis, the sagittal suture in the oblique diameter, the lesser fontanel high up and posterior.

Immediately above the plane of pelvic outlet the head rotates about its transverse axis, so that the chin recedes from the chest, the brow descends, and, if there is a high grade of pelvic contraction, becomes arrested in the diagonal at the anterior pelvic wall; this leads to a fatal dystocia. In other cases the brow rotates into the conjugate and becomes arrested at the symphysis, so that the greater periphery of the head (fronto-occipital 13⅝ in. or 34 cm.) passes through the outlet (Figs. 27, 28). Owing to the posterior position of the broad occipital region, the perineum is often torn.

Prognosis.—Less favorable than mechanism I., either when the entire head comes to a standstill or the brow alone is arrested in the plane of pelvic contraction by impinging on the anterior wall.

Treatment.—See § 2.

§ 14. **Brow Presentation** (Figs. 29 to 33, and 13 in the text).—Brow and face presentations are closely related to one another, the latter being often produced from the former, hence the conditions at the beginning of labor are usually the same.

The usual and relatively more favorable presentation is with the brow in front.

Palpation when the head enters in the first brow presentation shows the sagittal suture in the left maternal side in the transverse diameter; the brow presents; on the right side the examining finger feels the face and

nose, on the left the greater fontanel and a part of the sagittal suture.

After the head has performed the first rotation, about the transverse axis, the brow descends still lower; after the second rotation, about the lesser oblique diameter, the brow appears in the second oblique diameter (Fig. 30).

Palpation when the head enters the plane of pelvic contraction (first and second rotations) shows the brow to be low down, the upper portions of the face being felt with

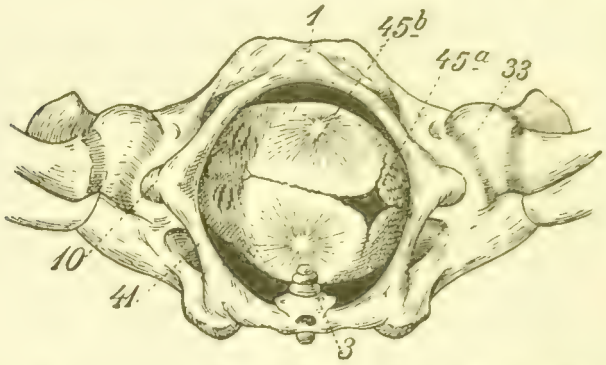

FIG. 13.—Brow presentation; sagittal suture in the median position between the transverse and second oblique diameter of the plane of the pelvic outlet.

greater ease than the vertex; the brow is found to the right by the side of the symphysis.

At the pelvic outlet the third rotation occurs about the transverse axis, the upper jaw becomes arrested at the symphysis, under which the brow appears, so that the occiput emerges over the perineum (Figs. 31 and 32).

The protection of the perineum is especially important in this presentation. The face and chin are the last to appear under the symphysis (Fig. 33). Characteristic configuration of the head (see Table I. in § 5).

Prognosis and Treatment.—See § 15.

§ 15. **Face Presentation, Chin Posterior** (Figs. 40 to 42, and 8 in the text).

Lateral deviation of the presenting portion of the

head, which produces the most unfavorable brow presentation, may correct itself, and labor may progress favorably if the head continues to descend in the same direction, and the brow presentation is converted into a face presentation by descent and anterior rotation of the chin. If, however, the chin rotates posteriorly and a part of the breast even forces itself into the hollow of the sacrum, the outlook is most unfavorable. At the plane of pelvic outlet the vertical line of the face is in the oblique diameter, with the chin posterior.

Causes.—Anomalies of position discussed in §§ 13 to 15 arise from the same causes, viz., excessive size, immobility, and an unyielding condition of the fetus (hard skull and deficient amount of amniotic fluid), combined with a more or less contracted pelvis and more or less obliquity of the longitudinal axis of the fetus (pendulous abdomen, incorrect position of the woman, mistakes in operative technic—such, for instance, as traction with the forceps in the wrong direction, etc.).

Palpation in the first face presentation—fetal back to the left and in front, fetal heart-sounds in the same position, chin to the right and posterior in the plane of the pelvic outlet (Fig. 12 in the text and Fig. 40)—shows the brow to the left and in front, the chin to the right and behind; low position of the chin.

If the chin becomes arrested in the hollow of the sacrum, labor comes to a standstill unless the fetus is immature or dead and therefore offers little resistance. The cranium is flattened against the anterior pelvic wall (see Fig. 42), and the vertical line of the face ultimately rotates in the anteroposterior diameter (Fig. 41); the chin is felt immediately in front of the tip of the sacrum.

The chin appears first over the perineum and the brow and occiput later emerge under the symphysis (Fig. 42). The perineum must be carefully protected. The face turns toward the mother's right thigh.

Prognosis.—Spontaneous delivery of a living fetus is practically impossible. It is as little to be expected as

the birth of a mature fetus in unfavorable brow presentations.

Treatment.—Before the head is engaged, version. After the head is engaged, if there are any indications for rapid interference, an attempt may be made to correct the presentation either by manipulation or with the forceps, by converting it into a vertex presentation. If this attempt fails and the head has engaged, nothing remains but perforation and craniotomy, unless the operator should succeed in drawing down the chin in brow presentations. In the case of face presentations when the chin is posterior, the latter may be brought forward and the child may then be extracted with the forceps (see § 20, I.).

§ 16. **Presentation of the Anterior and of the Posterior Ear.**—These represent the extreme degrees of the deviations which have been described as presentations of the anterior and posterior parietal bones (§§ 7 and 8). At the beginning of labor the sagittal suture may be felt, but as labor progresses it is gradually pushed up over the promontory or the symphysis. These presentations may also develop from brow and face presentations.

Prognosis.—The conditions are unfavorable and call for operative interference whether the cause be a greatly contracted pelvis or an abnormally large head (compare § 8

CHAPTER II.

UNFAVORABLE PRESENTATIONS IN BREECH POSITIONS.

§ 17. **Footling Presentations** (Plate 11, Figs. 44, 45, 86 to 89 *et seq.*).

Footling presentations, especially when complete, are unfavorable, because the dilatation of the cervix is much less perfect than in breech presentations. Accordingly there is great danger of the head becoming arrested, and the umbilical cord is not protected by the thighs.

Causes.—Either labor begins with a breech presentation and the legs prolapse, or the fetal trunk lies obliquely across the pelvic inlet, so that the breech impinges on one of the iliac bones and the feet come to lie above the os. The same thing happens with the upper extremity in head presentations; but, whereas in head presentations the arrest of the part against the lateral wall of the pelvis leads to a complete deviation, in other words a transverse presentation; in the case of the lower extremities, owing to the greater size of the presenting part, a breech presentation usually results and becomes complete when the breech enters the os and the knees appear at the vulva. Its occurrence is favored by any pathological condition of the pelvis.

Palpation.—The position of the great toe in relation to the other toes and to the sole of the foot, and the direction of the knee must be noted in order to determine, if possible, which foot presents. The diagnosis is based on the position of the back.

Treatment.—Interference should be delayed as long as possible, in order that the os may be dilated slowly and completely. The heart-sounds must be carefully watched. As soon as the umbilicus makes its appearance, manual extraction.

§ 18. **Abnormal Mode of Escape of the Aftercoming Head and of the Upper Extremities** (Figs. 92, 93).

The back usually lies slightly to one side and in front. If it rotates backward, the occiput also turns toward the sacrum. As the head passes the pelvic inlet, either the brow impinges, or the chin moves away from the breast and becomes arrested above the symphysis. The latter mechanism is more unusual and far more unfavorable, because the head is obliged to pass in one of its larger diameters.

Treatment.—As long as the breech is movable and above the pelvic inlet, inaction, until the os is somewhat dilated, because the strength of the labor-pains may be sufficient to effect an anterior rotation of the back. After

the os is dilated, the anterior foot should be drawn down.

If the breech is immovable and high within the true pelvis, the fillet should be applied to the anterior groin and directed forward by exerting traction to one side and forward. If the breech is immovable and low down in the plane of pelvic contraction and the head is arrested with the brow against the symphysis, one finger should be hooked into the anterior groin so as to turn the trunk while the head is rotated at least into the transverse diameter—by Wigand-Martin-von Winckel's external method—and the head pressed down into the pelvic inlet.

If the head is immovable in the true pelvis, it should be brought into the transverse diameter by inserting one finger in the mouth, and the occiput rotated backward. Or the method just described may be combined with traction on the nucha (see Mauriceau-Veit-Smellie's method), whereby the occiput is delivered first over the perineum (see § 27, B).

The position may also be corrected, especially when the fetus is dead, by inserting a blunt hook into the canine fossa, being careful to protect the soft parts with the finger.

The Anterior Arm may Become Arrested or Pushed Behind the Occiput.

After the posterior arm has been freed (compare § 27, B), rotation of the fetus about its longitudinal axis through one-fourth of the pelvic periphery—that is, from the anterior extremity of one diagonal to the anterior extremity of the other—suffices to bring the other arm posterior. In some cases the anterior arm remains wedged fast behind the occiput.

Treatment.—The trunk is rotated through three-fourths of the pelvic periphery, first with the back against the sacrum and then into the other side.

CHAPTER III.

OBLIQUE AND TRANSVERSE POSITIONS (SHOULDER PRESENTATIONS (Plate 10, Fig. 48 *et seq.*, Fig. 75 *et seq.*).

In transverse positions the long axis of the fetal trunk forms an oblique angle with the long axis of the uterus, or at least with the plane of the pelvic inlet. These positions are divided according to their frequency as follows:

I. Variety: Head to the left. 1. Subvariety, back anterior.
II. Variety: Head to the right. 2. Subvariety, back posterior.

Shoulder positions are the most frequent (these include presentation of the elbow, arm, and hand).

Causes.—Excessive or diminished resistance during labor.

First, on the part of the *uterus*. Abnormal size and flaccidity of the walls in multiparæ, anomalies of form (developmental anomalies, tumors), anomalies of position (anteflexion with pendulous abdomen).

Second, on the part of the *fetus* and *ovum*. Placenta prævia, hydramnion, abnormally large or abnormally small fetus, immature births, monstrosities, incorrect positions (prolapse of an extremity), twins, maceration.

Third, on the part of the *pelvis*. Pelvic contraction, the most frequent cause.

Usually several causal factors act together, among which we may mention sudden discharge of the amniotic fluid, incorrect position or sudden movements of the woman.

§ 19. On external examination in transverse positions, head to the *left*, back *anterior* (the most frequent), the uterus appears unusually broad and the fundus is lower than normal. The head is felt as a hard roundish prominence on the left innominate bone. On the right, an irregular mass is felt which corresponds to the breech and hips. Between these is the broad mass of the back. The heart-sounds are heard above the symphysis.

Palpation at the onset of labor gives the following result: At first the pelvic inlet and the os are empty;

Plate 10.

Neglected Transverse Position I.a about to Change to Delivery Conduplicato Corpore.—The head impinges on the left innominate bone, the back is anterior, the shoulder in the pelvic inlet, the arm is prolapsed, very much swollen, and covered with excoriations from the maceration of the skin after the death of the fetus *sub partu*. Unless the membranes rupture early and the transverse presentation is spontaneously converted into a breech or head presentation by the force of the labor-pains, an event which is not likely to occur when an arm is prolapsed, the head and trunk are forced into the pelvic inlet at the same time, and delivery conduplicato corpore results. Owing to the interference with the circulation, the prolapsed arm becomes swollen and obstetric interference is difficult. The dangers are: discharge of the bactericidal amniotic fluid, which is not obstructed by a large presenting part, putrefaction of the dead fetus, and rupture of the overdistended lower uterine segment. Only an immature fetus can be delivered conduplicato corpore without danger.

later a small portion of the fetus is driven down, unless spontaneous evolution takes place; a little later the examining finger finds the shoulder or an elbow or a hand. Unless the latter has been twisted, the diagnosis of the entire presentation can at once be made. If, for instance, the thumb is directed to the left and the palm of the hand backward, it is the right hand (Fig. 49), or the reverse. As the head must be in the direction of the thumb, and the anterior surface of the child in the direction of the palm, we have transverse position I., head to the *left*, back *anterior*. To confirm the diagnosis, the position of the axilla and of the prominence of the shoulder should be investigated; the latter shows the direction of the head, and the relations between the scapula and clavicle reveal the position of the back, etc. In our case, therefore, the shoulder is in the left maternal side, the axilla presents toward the right, and the scapula faces the symphysis.

The subsequent course of labor varies.

(*a*) Partial spontaneous version may take place, and the transverse presentation be thus changed into a longitudinal one which will be either cephalic or pelvic, de-

pending on which pole of the fetus is lower. When a head presentation is converted into a breech presentation, we speak of total version.

This so-called spontaneous version occurs most frequently when the fetus is immature and the pelvis large (Figs. 57 to 59).

(*b*) Spontaneous evolution may be effected (see § 12, Figs. 55, 56). This mode of delivery occurs when the os is well dilated, the pelvis large, and vigorous labor-pains persist after the engagement of the shoulder. One-seventh of all mature infants born in this way live. Spontaneous evolution is a natural version at the pelvic outlet or in the true pelvis.

(*c*) Delivery conduplicato corpore may occur (see § 12, Figs. 51–54). A mature infant cannot be born alive in this way.

General Course and Prognosis of Labor.—The prospect for mother and child, when the transverse presentation of a mature fetus is left to itself and the resistance is marked, is unfavorable in the order of delivery above given, and the longer the duration of labor the more hopeless the prognosis. Any one of the three above-mentioned modes of delivery is far more dangerous than rational operative interference, especially manual version.

Dangers to the Mother.—The transverse distention of the uterus by the abnormal position of the fetus brings on excessive labor-pains and early bearing down, which result in premature[1] rupture of the membranes. As the pelvic inlet and the os are unobstructed, the greater part of the amniotic fluid is discharged and permits the entrance of air into the uterine cavity. The increased irritation of the uterine wall results in swelling of the genitalia (with consequent danger of injury and infection), and this in turn increases the force of the labor-pains. By virtue of its own contractility, the fundus retracts

[1] *Premature* rupture of the membranes occurs before the onset of labor-pains; *early* rupture, before complete dilatation of the os.

over the fetal body and overstretches the lower uterine segment, which in addition is bruised by the pressure of the head. If this condition persists, we speak of neglected transverse presentation (compare Plate 10): the contraction-ring ascends a hand's breadth or more above the umbilicus,[1] and the uterus is in great danger of rupturing; the labor-pains become tetanic, and it may be impossible and dangerous to introduce the hand (contraindication to version).

In addition to lacerations due to the traction and compression, we may have contusions and erosions of the soft parts by the pressure of the promontory or other prominences at the joints or along the bones of rhachitic pelves (compare *Atlas of Obstetric Diagnosis and Treatment*, second edition, § 20, No. 12).

For the diagnosis and prophylaxis of these complications, see *Atlas of Obstetric Diagnosis and Treatment*, second edition, §§ 6, 18, 20, and Plates 67–71, Figs. 16–18 in the text.

Dangers to the Child.—The child is in even greater danger than the mother. In protracted labors it is apt to become asphyxiated by premature detachment of the placenta, tetanic contraction of the afferent vessels in the uterine walls, prolapse and compression of the umbilical cord, protracted compression of the brain-centers.

Treatment.—Before the rupture of the membranes, the position should be corrected by external, and later by combined, manipulation or by version. If the latter is contraindicated, perforation or embryotomy (compare § 8 in regard to indications by the conjugate).

[1] Lower uterine segment and traction-ring. See *Atlas of Obstetric Diagnosis and Treatment*, second edition, §§ 6 and 20.

PART B.

Obstetric Operations.

GROUP I.

Simple Obstetric Operations on the Fetus and Ovum.

A. Preliminary "Purely Obstetric" Operations on the Fetus and Ovum.

(*a*) Operations for the purpose of correcting the position of the fetus.

1. Conversion of face and brow presentations into vertex presentations (Figs. 95–97) (§ 20, I.);

2. Conversion of unfavorable face and brow presentations into favorable face presentations (§ 20, II.);

3. Conversion of a breech into an incomplete footling presentation (§ 20, III.).

(*b*) Replacement of prolapsed parts (§ 21):

1. Prolapse of the umbilical cord;

2. Prolapse of the extremities (Figs. 46, 49, 55, 86, 98, 122).

(*c*) Rupturing the membranes and puncture of the amniotic sac (§ 22).

(*d*) Version (§ 23):

1. External version (Wigand's method) (Fig. 75);

2. Combined direct and indirect version with one to three fingers, when the os is insufficiently dilated (Figs. 76, 79–81) (methods of Hohl-Braxton Hicks and von Hecker);

3. Combined direct and indirect internal version with the entire hand, when the os is fully dilated (Figs. 43, 77, 78, 82–86):

α. Cephalic version (after d'Outrepont, Fig. 77, and Busch, Fig. 78);

β. Podalic version by one or both feet, after Ambroise Paré (Figs. 43, 82–85).

(*e*) Perforation and cranioclasis, cephalotripsy (Figs. 119–121, 126) (§ 24);

(*f*) Embryotomy (decapitation, exenteration, cleidotomy) (Figs. 118, 122, 126 d) (§ 25);

B. "Purely Obstetric" Operations on the Fetus and Ovum during Labor.

(*a*) Extraction of the living child:

1. Manual expression by pressure on the abdominal walls (§ 26):

α. Extraction of the head from the perineum after Ritgen-Fehling and Smellie-Ritgen (§ 1, Figs. 10 and 11):

β. Of the trunk after Kristeller (§§ 1 and 4, Figs. 13 and 110);

γ. Of the aftercoming head after Wigand-A. Martin-v. Winckel (§ 4, Fig. 72);

δ. Expression of the placenta after Credé (§ 1, Fig. 18).

2. Manual extraction (§ 27):

α. In breech presentations (Figs. 65, 67, 68);

β. In footling presentations (Figs. 44, 45, 62–64, 69–71, 87–91);

γ. Of the aftercoming head after Veit-Smellie-Lachapelle-Mauriceau) (§ 4, Figs. 73, 74);

δ. By the shoulder (§ 1, Figs. 13, 110);

ε. Of the placenta by traction on the umbilical cord (§ 1).

3. Instrumental extraction (§ 28):

α. With forceps

In cranial presentations (Figs. 99–101, 105, 106–110) and

In presentation of the anterior fontanel (Figs. 112–115);
In face presentations (Figs. 115–117);
In deep transverse presentations;
Of the aftercoming head (Fig. 118);

3. With the blunt hook or the fillet (§ 27, A, Fig. 68) (strip of iodoform gauze).

4. Manual separation of the placenta (§ 1, Fig. 19):

(*b*) Extraction of the fetus with the craniotractor or cranioclast, with the bone forceps or with a sharp hook (§§ 24, 25) (Figs. 120, 126 *a*, *b*, *c*).

GROUP II.

Surgical Obstetric Operations on the Mother.

A. Induction of Abortion and Premature Labor (§ 31).

(*a*) Dilatation and preparation of the cervix;
(*b*) Induction of labor-pains, separation of the ovum.

B. Surgical Dilatation of the Parturient Canal (§ 32)

(*a*) Episiotomy for the purpose of dilating the perineum or vagina;

(*b*) Incisions into the os and portio vaginalis or vault of the vagina, and accouchement forcé.

C. Delivery of the Child by Artificial Means.

1. Cesarean section (Figs. 123–125) (§ 33);

2. Supravaginal amputation of the uterus after Porro (§ 33);

3. Celiotomy after rupture of the uterus, for the removal of tumors, and in ectopic gestation (§ 33);

4. Symphyseotomy (§ 34).

D. Surgical and Other Obstetric Procedures Immediately after the Completion of Labor.

1. Primary repair of perineal tears and injuries about the vulva, and of incisions (§ 35).

2. Repair of lacerations in the cervix and vault of the vagina, or of incisions (§ 36);
3. Tamponade of the uterus and vagina (§ 36);
4. Irrigation of the uterus with or without removal of secundines (§ 36).
5. Atmocausis (vaporization) (§ 36)

GROUP I.

The Methods of Performing the "Purely Obstetric" Operations on the Fetus and Ovum.

CHAPTER I.

PRELIMINARY "PURELY OBSTETRIC" OPERATIONS ON THE FETUS AND OVUM.

§ 20. Operations for the Purpose of Correcting the Position of the Fetus.

I. Conversion of Face and Brow Presentations into Vertex Presentations (Figs. 95–97).

Indications.—Face presentation, chin posterior; any brow presentation. When the following conditions are present: Head high and movable above the inlet; absence of marked resistance in the parturient canal; absence of imminent danger calling for immediate delivery.

Three methods:

1. *When the Os is Closed or only slightly Patulous and the Membranes are Intact.*—The lordosis of the vertebral column is corrected by external manipulation (Schatz's method). With one hand the operator draws the shoulder toward the child's occiput and raises it from the inlet, while with the other the breech is pushed toward the opposite side (Fig. 95).

By thus restoring the cervical vertebræ to their normal kyphotic condition, the face is drawn up and away from the pelvic inlet; the vertex engages or is pressed into the pelvic inlet.

The operator stands on the side corresponding to the occiput of the fetus. After the operation has been successfully completed, the woman is placed on the side opposite the fetal occiput, and, after the head has engaged in the pelvis, she is placed on the side corresponding to the lesser fontanel.

2. *When the Os admits Two Fingers.*—By combined internal (two or three fingers) and external manipulation (Baudelocque's method) the chin is pushed up and away from the pelvic inlet with the internal hand, while the occiput is pressed down with the external hand. This method may be combined with the first (Fig. 96).

3. *When the Os admits the Entire Hand and the Membranes have just been Ruptured, either Spontaneously or Artificially.*—The entire hand is introduced (Playfair-Partridge's method) and the head guided directly downward. The following modification of Thorn's method gives the best results: The chin is first pushed up from within by the indirect method, while the shoulder is raised and forced backward from without; then the occiput is seized directly with the entire internal hand and guided downward, while the external hand, by pushing on the breech, brings the trunk into the kyphotic attitude. If the occiput lies on the mother's left side, as in presentation I., the operator introduces the right hand (Fig. 97).

This method may, with the help of an assistant, be combined with the first and second; that is, the assistant may raise the trunk and push it to the desired side from without, while the face is pushed upward and the occiput brought down from within (Ziegenspeck).

II. Conversion of Unfavorable Face and Brow Presentations into Favorable Face Presentations.

Indications.—Face presentation with chin posterior; any brow presentation, providing the head is fast in the pelvis and the child is alive; otherwise, perforation and craniotraction.

Two methods:

1. *In Brow Presentations.*—The brow is pushed upward with the thumb, while the remaining fingers bring the chin down so as to produce a face presentation by gradually rotating the head about its transverse diameter (Rose).

2. *In Face Presentations with Chin Posterior.*—During an interval between labor-pains, the head is rotated by applying the thumb and fingers to the brow and chin, so that by from six to eight movements the chin is brought anterior. During the labor-pain the chin must be held fast, to prevent its slipping backward and to bring about a resultant anterior movement (Volland).

III. Conversion of a Breech into an Incomplete Footling Presentation.

Necessary Conditions.—1. The breech must not be fixed in the small pelvis. 2. The os must admit the hand. 3. The membranes must be intact or but recently ruptured; that is to say, there must not be any undue tension of the lower uterine segment.

Indications.—1. Disproportion between child and the parturient canal (abnormal size of the child, pelvic contraction, rigidity). 2. Unfavorable presentation (lateral deviation of the breech with the back posterior and the face in front, so that the chin is apt to catch on the symphysis). 3. Conditions threatening the life of the child (prolapse of the cord, asphyxia). 4. Conditions threatening the mother (hemorrhage, eclampsia).

Method.—The anterior foot is drawn down, so as to

bring the back forward, the operator inserting the hand corresponding to the foot to be brought down (Fig. 87). If, as rarely happens, the leg is extended, it must first be flexed at the knee, as traction should be applied only to the foot.

§ 21. Replacement of Prolapsed Parts.

I. Prolapse of the Cord.

Causes.—Failure of the presenting part to fill the pelvic inlet and os (transverse presentation, breech presentation, lateral deviation of the head).

Treatment.—A. *In Cephalic Presentations.*—1. When the os is insufficiently dilated:

(*a*) Instrumental replacement, as for instance with v. Braun's apotheter, consisting of a staff of guttapercha 19½ in. (½ meter) in length, provided with an eye through which the loop of a fillet is passed.

(*b*) Combined version if the first method fails.

2. When the os admits the hand:

(*a*) *Manual Reposition.*—The woman is placed on the side corresponding to that of the prolapsed cord, and the latter is pushed back into the uterus until a point is reached where it is not exposed to pressure between the uterine wall and the presenting part. When this has been accomplished, the patient is carefully placed on the other side, so that the trunk in changing its position presses the presenting part firmly into the pelvis.

Indications for Replacement.—In *cephalic positions* (including face presentations): When the os is insufficiently dilated (instrumental); when, although the os admits the hand, there is no indication for immediate delivery;

In Breech Positions.—When the os is not sufficiently dilated;

In Transverse Positions.—When the os is not sufficiently dilated.

Necessary Conditions for Replacement.—1. The child must be alive. 2. The os must admit the hand

(else instrumental reposition). 3. The head must be movable. 4. Primiparæ must be anesthetized. The woman must be placed on that side which corresponds to the position of the prolapsed cord.

Reposition is completed when the cord has been pushed above that part of the uterus which surrounds the presenting part of the fetus; that is, when it lies above the iliopectineal line in the false pelvis. The patient must then be immediately placed on the other side.

(*b*) Podalic version and immediate extraction if the child is in danger (recognized by weak pulsation of the cord), provided: 1, that the head is still movable and in an unfavorable position (in a contracted pelvis); and 2, an extremity is prolapsed in addition to the cord.

(*c*) Forceps when the head is low. The os must be completely dilated, and great care must be exercised to avoid including the cord in the grasp of the forceps.

B. In Breech Positions.—(*a*) Replacement in breech positions when the os is not sufficiently dilated (instrumental);

(*b*) Extraction when there is danger and the os is sufficiently dilated for the passage of the aftercoming head; in breech presentations, the foot must be brought down.

If the fetus is astride of the umbilical cord, the placental portion must be freed by drawing it down over one extremity (Fig. 64).

C. In Transverse Positions.—(*a*) Replacement, when the os is insufficiently dilated (instrumental);

(*b*) Podalic version and extraction when the os is sufficiently dilated. The term presentation of the umbilical cord is used when the cord lies by the side of or beneath the presenting part, and the membranes are intact.

Treatment.—Prophylaxis (applicable also in prolapse of the cord). The woman must immediately be placed on the side corresponding to the position of the prolapsed portion; by this maneuver the trunk falls toward this

side, and the head is directed to the pelvic inlet by the pressure of the fetal vertebral column and the altered direction of the uterus. In some cases the knee-chest position may be necessary. The woman must be forbidden to exert abdominal pressure for some time, and the membranes preserved intact as long as possible.

II. Prolapse of the Extremities.

(Figs. 46, 49, 55, 86, 98, 122.)

Broadly speaking, prolapse of the extremities includes abnormal attitudes of the fetus and abnormal presentations of the head; but in the narrow, obstetric sense, prolapse of the extremities is applied to head presentations only when one or more extremities lie in apposition with the presenting vertex, sinciput, or face. The prolapse of the upper extremities in breech and transverse presentations has no effect on the course of labor.

As in the case of the umbilical cord, we distinguish between presentation and prolapse. The most favorable presentation of extremities when the membranes are intact is that of both hands in apposition to the head. Presentation of the elbows is distinctly more unfavorable.

When the membranes rupture, the extremity glides into the vagina; the presentation is converted into a prolapse, which usually occupies the hollow of the sacrum and is often combined with prolapse of the cord.

Etiology.—Incorrect position and presentation owing to abnormality in the shape of the uterus (developmental anomaly, tumor, or displacement owing to pendulous abdomen, hydramnion, twins), or to pelvic contraction, because, owing to the prominence of the promontory, a large portion of the membranes occupy one-half of the pelvis and may permit an extremity to slip down into it. Immature fetus.

The accident may be brought about by unfavorable position and sudden movement on the part of the mother.

The result may be a lateral deviation of the presenting part; a vertex presentation may then be converted into presentation of the sinciput or face, or, if the head is high, a transverse presentation may be produced (compare Figs. 46–49). If the arm is behind the symphysis, the sagittal suture moves toward the promontory, and presentation of the anterior or of the posterior parietal bone results. If the foot prolapses, lateral deviation of the head is liable to result on account of the marked kyphosis of the spinal column.

Treatment.—In transverse and breech presentations no treatment is required, unless it be to apply a fillet to the prolapsed extremity. The mother should be placed on the side corresponding to the position of the head.

In *Cephalic Positions.*—A. Prolapse of the upper extremity:

1. Head movable in the pelvic inlet or "extramedian."

(*a*) Manual replacement. The woman is placed on the side corresponding to the prolapsed extremity, so that the extramedian deviation of the head is increased and leaves the passage free. The head, of course, always deviates to the side opposite to that of the prolapse. By placing the woman in this position, the deviation of the head is increased by the change in the position of the trunk.[1]

The arm is then seized at the elbow with the entire hand and pushed upward (Fig. 98), and the head pressed into the pelvic inlet from without. It may be necessary to anesthetize the woman and place her in the knee-elbow position. After reposition has been effected, the woman should be placed on the side opposite to the prolapse. For successful performance of replacement, see under Prolapse of the Umbilical Cord.

Indications for Replacement. —. Extramedian

[1] In some cases it is better to place the woman on the side opposite to that of the prolapsed extremity, because the trunk then draws the arm upward and presses the head downward.

deviation of the head in consequence of prolapse of the extremity, recognized by the incorrect position of the head at the pelvic inlet and swelling of the arm. Contraindicated when the life of the mother or child is in immediate danger (hemorrhage or tetanus uteri).

Necessary Conditions.—1. The arm must not have prolapsed beyond the vulva. 2. The lower uterine segment must not be unduly stretched. 3. The head must be movable. 4. The os must admit the entire hand.

(*b*) Podalic version when manual replacement fails and the head is still movable.

2. When the head is firm and low down in the true pelvis, expectant treatment; if there is immediate danger, forceps, taking care not to include the prolapsed arm.

B. Prolapse of a lower extremity occurs, as a rule, only when the fetus is dead or immature.

Treatment.—The same as for A. If manual replacement fails, the child is extracted after the head has been pushed back (Fig. 86). Before resorting to this procedure, the existence of twins must be excluded, as one may present by the head and the other by the foot. In performing replacement, the operator seizes the knee. If, however, the head and a lower extremity are wedged fast, the choice lies between forceps and perforation.

§ 22. Rupture of the Membranes and Perforation of the Amniotic Sac.

Artificial rupture of the membranes is permissible only when the os is fully dilated and the membranes interfere with the advance of the head or threaten to bring on separation of the placenta (causing hemorrhage, asphyxia of the fetus), or for the purpose of determining whether the head has entered the pelvic inlet. In the latter case, a vaginal examination must be made at once. A distinction must be made between distensible and thick membranes. The former may bulge as far as the vulva if there is a large quantity of amniotic fluid, constituting prolapse of the membrane (Fig. 4). They are less apt to interfere with labor than are thick membranes; the latter may be opened with a mandril or a disinfected knitting-needle, taking care to avoid

blood-vessels, the opening of which might cause the death of the fetus. The procedure is indicated when the body of the uterus becomes painful to the touch, owing to excessive distention of the uterine muscle.

The ovum is punctured for the purpose of inducing premature labor,[1] which usually comes on from one to two days after the operation. The woman must remain quietly on her back to prevent an excessive discharge of amniotic fluid, partly because the child would thereby be exposed to danger by the increased pressure, and partly because of the greater difficulty of dilating the parturient canal. The operation is performed with a mandril or trocar at the internal os (Scheel's method), or as high as possible above the internal os (Hopkins-Meissner).

§ 23. Version.

Version is divided into total and partial; total, when one longitudinal position is converted into the other, as for instance a face into a footling presentation; partial, when a transverse is converted into a longitudinal position.

Version is further divided into external and combined; that is, version by external and internal manipulation. The latter may be performed either with two or three fingers or with the entire hand, depending on the dilatation of the os, and they may act indirectly or directly on the part thus brought down, according as the internal hand brings the desired part directly down or merely pushes aside the part that happens to be presenting, and thus indirectly enables the favorable part to descend or to be pressed down by the external hand.

A. External Version (Wigand's Method) (Fig. 75).

Necessary Conditions.—1. The membranes must be intact. The most favorable moment is at the end of the period of dilatation or immediately after the rupture of the membranes; in any case, the child must be perfectly movable. 2. The absence of imminent danger to mother and child.[2] 3. Absence of serious obstacles to the expulsion of the fetus in the presentation to be produced—as, for instance, pelvic contraction. 4. The conditions must be such that the external manipulations can be performed with ease and certainty (the abdominal walls must not be too fat, there must be no tumors, ascites, tenderness of the uterus, etc.).

[1] For other methods and for indications and necessary conditions for the induction of abortion and premature labor, see § 31.

[2] Among these dangers, v. Winckel does not include prolapse of the cord in transverse positions. In such cases, he recommends instead of internal version that the position be converted into a cephalic one and the umbilical cord then replaced.

Preparatory Treatment.—Relaxation of the abdominal walls by raising the thorax, drawing up the legs, and reassuring the woman—if necessary, anesthetization; evacuation of the bladder and rectum. Version is performed in the intervals between labor-pains. The woman is placed on her back.

Indications.—1. Transverse positions of a mature fetus. 2. Rarely in longitudinal presentations when the opposite longitudinal presentation would be more favorable and would enable the operator to terminate labor more easily by artificial means.

Method.—Dorsal position. Cephalic version is usually performed because the necessary conditions for this presentation are the most favorable; if cephalic version fails, podalic version is selected. Between the labor-pains the head is seized and placed above the pelvic inlet, while with the other hand the breech is directed upward (Fig. 75). During each labor-pain the vertex is forced into the pelvic inlet.

If version is successful—recognized by making a vaginal examination, the other hand fixing the head from without—the woman is laid on the side corresponding to the position of the occiput. If necessary, the membranes may be ruptured. It is well to support the uterus by means of a cushion.

B. Combined Direct and Indirect Version with One to Three Fingers, when the Os is Sufficiently Dilated.

(*a*) Indirect version according to Hold and Braxton Hicks. One or two fingers are introduced into the os and the presenting shoulder is pushed to one side; with the other hand the desired portion (breech) is pushed down into the pelvis. The foot is then drawn down into the cervical canal. This form of version can be performed in the early stage of labor, and, as in the foregoing, the patient need not be anesthetized. 1. Cephalic, Fig. 76. 2. Podalic (one foot or both feet) (Figs. 79 and 80).

Necessary Conditions.—1. The membranes must be intact or but recently ruptured. 2. The os must admit one or two fingers.

Plate II. [4]

FIG. 1. **Position of Placenta Prævia Marginalis at the Internal Os before the Onset of Labor-pains** (modified from preparation of Ahlfeld). —As soon as pressure on the amniotic sac begins, the anterior pole is forced down into the cervical canal, while the labor-pains at the same time actively dilate the internal os and the cervical canal. This will tend to loosen that portion of the placenta which projects over the internal os, and the consequent rupture of some of the vessels will produce hemorrhage. Rupture of the membranes would, therefore, remove one cause of separation and consequently of hemorrhage.

FIG. 2.—After the rupture of the membranes, the head presentation is converted into a footling presentation by introducing two fingers into the os after Braxton Hicks, and one foot is brought through the insufficiently dilated cervical canal into the vagina. The lower extremity presses the loosened lobe of placenta against the uterus and thus effectually arrests the hemorrhage.

Indications.—1. Placenta prævia (Plate 11).

Symptoms.—Hemorrhage during pregnancy (see *Atlas of Obstetric Diagnosis and Treatment*, second edition).

Treatment of placenta prævia (insertion in the lower uterine segment; cause, endometritis):

(*a*) When the cervix does not admit the finger, tamponade (iodoform, itrol, nosophen gauze), with patient in lateral position.

(*b*) When the cervix admits one or two fingers, rupture of the membranes; combined podalic version by one foot (Braxton Hicks), followed by tamponade. If the hemorrhage continues, the foot is drawn down so as to make the breech act as a tampon. In private practice it is advisable even at this time to persist in the expectant treatment with gauze tampon (Kehrer), or dilatation of the cervix may be practised; the author has seen this treatment followed by good results to both mother and child. It is necessary, however, that the presenting portion of the trunk be firmly wedged in the os, or that the gauze tampon be inserted high up and firmly packed. Dilatation of the cervix may be effected gradually by means of graduated rubber bags, or forcibly by making traction on the rubber bag. Quite frequently both the traction on the prolapsed portion of the placenta and the hemorrhage cease as soon as the membranes are ruptured spontaneously or artificially. In such cases, dilatation of the vagina suffices.

(*c*) When the os admits the hand, internal podalic version and extraction. If the os is dilated, extraction after the method most favorable to the child (see Chapter II., A).

In the case of hemorrhage during pregnancy, induction of

Fig. I

premature labor and Braxton Hicks's method; in placenta prævia centralis, perforation of the placenta.

2. Transverse presentations when the membranes have ruptured before the cervix is sufficiently dilated.

3. Head and transverse presentations with prolapse of the cord and insufficiently dilated os.

(*b*) *Direct method* of v. Hecker (Fig. 81).

Indications.—Whenever the os is insufficiently dilated and the method just described is impossible owing to the early discharge of the amniotic fluid and the constriction of the fetus by the uterine muscle. In prolapse of the shoulder, it is well to know that it is possible to insert two or three fingers alongside of the shoulder and reach the posterior knee. While the latter is drawn directly down, the breech may be pressed downward from without with the other hand.

C. Combined Direct and Indirect Internal Version with Entire Hand, when the Os is completely Dilated (Figs. 43, 77, 78, 82–86).

(*a*) **Cephalic** (Figs. 77, 78).

Necessary Conditions.—1. The os must admit the entire hand. 2. The head must be movable above the pelvic inlet. 3. The lower uterine segment must not be unduly distended, the contraction-ring not higher than 2–3 in. (5–7.5 cm.) above the symphysis (cf. page 18). 4. The pelvis must not be excessively contracted (cf. § 8) (limit of conj. vera 3 in. = 7.5 cm.). 5. The membranes must be intact or but recently ruptured. 6. The pelvis must be normal, so that the head can easily engage and there is no likelihood of a subsequent podalic version being necessary. 7. Absence of immediate necessity for rapid delivery (prolapse of the cord; compare necessary conditions in Wigand's method).

Indications.—Transverse presentations whenever the methods given under A and B have failed.

Method.—It is always performed with the woman on the side corresponding to the part to be brought down. The operator introduces that hand the palm of which is opposite to the woman's abdominal surface.

α. Combined direct internal version (Busch-Braun method, Fig. 78): The occiput is seized with the internal hand and brought into the pelvic canal; the external hand assists by pushing up the breech. This method is possible when the membranes are intact or have recently ruptured, and but little amniotic fluid has been discharged.

β. Combined indirect internal version (d'Outrepont's method, Fig. 77): The presenting shoulder is pushed to one side by the internal hand, while the external hand presses the occiput into the true pelvis. This method is employed when a large portion of the amniotic fluid has escaped and the trunk and head are tightly embraced by the uterus.

(*b*) Podalic version by one or both feet (Ambroise Paré, 1550, Figs. 43, 82–85).

Necessary Conditions.—The same general conditions as in podalic version under 1–4, and in addition

Special Conditions for Podalic Version:

5. The pelvis must be large enough for the evolution of the fetal trunk; in other words, it must allow the hand to pass easily; conj. $2\frac{3}{4}$–$3\frac{1}{4}$ in. (7–8 cm.).

6. In primiparæ the os must be completely dilated, in multiparæ nearly so; that is, it must measure at least $2\frac{3}{4}$ in. (6 cm.) across, otherwise the head will not pass.

7. The child must be nearly or quite mature; an immature fetus will be delivered by spontaneous evolution (compare § 12).

Indications.—α. To correct transverse positions when the fetus is more than twenty-eight weeks old, even though it be dead. If the fetus is macerated in the third degree, evolution conduplicato corpore may be attempted.

β. In cephalic positions, when the head is movable in the pelvic inlet:

1. In improper engagement[1] of the brow and face or in obliquely contracted pelves, if the occiput is above the narrower side (compare §§ 7, 8, 14, 15), especially in brow and face presentations, chin posterior. *Treatment.*—At first expectant, unless there is immediate danger.

2. In moderately contracted pelves, when the head fails to descend and constantly tends to change its position, or when it is learned from the history of former labors that a breech is more favorable than a cephalic presentation. Version as a prophylactic measure.

3. In normal pelves, when there is sudden danger and the head is still movable and the forceps cannot be used; this is always an indication for immediate extraction. It happens, for instance, in placenta prævia.

4. In prolapse of extremities or of the umbilical cord, when replacement has failed.

5. In cases of double monsters.

6. After perforation and crushing of the skull, when the child cannot be delivered by traction on the remains of the skull.

7. In rupture of the uterus, with escape of the child into the abdominal cavity.

Method.—The woman is placed on the side corresponding to the part to be brought down (Fig. 82). The operator stands behind the patient and introduces his right hand, folded into a cone, if the woman is lying on her left side, and *vice versa*; with the other hand, version is assisted through the abdominal walls. The patient must be anesthetized. The extremities are more readily seized when the woman is in the lateral position; occasionally the knee-elbow position is more satisfactory.

a. In **oblique positions** (Figs. 82–85):

If the back is in front, the presenting foot which is underneath is brought down and version performed (Fig. 83). When the back is behind, the presenting foot which is underneath is first brought down (Fig. 84) and after that the upper foot is seized and version performed (Fig. 85).

The reason is that extraction is easiest when the back lies in front, toward the symphysis, as otherwise the chin,

[1] Compare pages 13 and 14.

which is anterior, is apt to catch on the symphysis, and the above manipulations are for the purpose of producing this anterior rotation. If the fetus is in the transverse position with the back posterior, so that it is impossible to bring down the upper foot, the trunk must be rotated by twisting the lower thigh after it has been brought down. If one of the extremities presents, it should be secured with a fillet (Fig. 82). Traction must be uniform and in the proper direction, so that the back becomes anterolateral or remains in that position.

Version is completed when the knee is in the vulva; the breech has then entered the pelvic inlet and the desired longitudinal position has been achieved.

β. In **cephalic positions** (Figs. 43, 86):

Either the anterior foot or both feet are brought down (Fig. 43). With the other hand on the fundus uteri, the breech is pushed downward and the head upward. If the attempt at rotation is blocked by the failure of the originally presenting part to move away from the pelvic inlet, it should be pushed aside from within, traction being at the same time applied to the foot by means of a fillet. This is the so-called "double method of Madame Siegemund," 1690 (Fig. 86). Or it may be possible to push the head aside with the thumb and to seize the foot with the first and second fingers.

---

§ 24. **Perforation and Cranioclasis, Cephalotripsy** (Figs. 119–121, 126).

Perforation.—Either Levret's and Naegele's cutting perforators (Fig. 119) or boring instruments, such as Kiwisch's trephine, are used. The head is fixed through the abdominal wall and the perforator introduced, guided by two fingers. If cutting instruments are used, the fontanels and sutures should be selected; if the trephine, the bones, preferably the parietal. After the opening has been enlarged in the shape of a cross, the brain is

incised in all directions and removed with the finger and by irrigation with the vaginal douche down to the bulb (*nœud vital*) of the medulla. In face presentations the frontal bone is perforated and one blade of the cranioclast inserted in the mouth, while the other is applied to the throat so that the lower jaw is grasped between the two blades (Kehrer). In extracting the aftercoming head, the posterior lateral fontanel behind the ear is sought for. The child's trunk is held on one side. The woman is placed across the bed, with the trunk elevated and the buttocks at the edge of the bed, legs wide apart, and feet supported on two chairs. An anesthetic should be given if only for ethical reasons.

Cranioclasis.—After the brain and meninges have been incised in all directions and removed from the calvarium by irrigation, the inner blade of the cranioclast (K. v. Braun's, Fig. 120, Kehrer's,[1] Auvard's) is introduced into the skull under the guidance of two fingers. Then the second outer blade is applied to the outer surface of the skull, care being exercised to avoid seizing any of the maternal soft parts or fetal membranes (Fig. 121), and then the two blades are brought together and locked with the screw. In this way the skull is crushed and securely seized. This is immediately followed by extraction (craniotraction) in the direction of the pelvic axis, the instrument being slightly twisted so as to prevent its slipping.

In some cases the instrument slips so frequently that at last nothing remains but the base of the skull, and there is nothing for the instrument to take hold of; in such cases, the cephalotribe must be used. This instrument was originally employed only to crush the skull, just as the cranioclast is really an instrument designed for traction; but in its modified form devised by Busch, the blades, which are unfenestrated and provided on their inner surface with teeth, can be brought securely together by means of a compression-screw similar to that on a cranioclast, so that a very firm hold on the remains of the crushed skull is obtained. This is practically the only way the cephalotribe is now used. Perforation and craniotraction may occasionally, in contracted

[1] Kehrer's unfenestrated cranioclast with serrated jaws.

pelves, be applied to the breech if the latter fails to descend, and traction with the fillet or blunt hook, or by bringing down one foot, is impossible.

A rather dangerous instrument, on account of its tendency to tear through the tissues, but one which is almost indispensable, if for instance the entire calvarium has been removed, is Levret's sharp hook (Fig. 126 *b*). In a case of this kind, when there was no sharp hook at hand, the author overcame the difficulty by getting the midwife to perform Kristeller's method, while he himself seized the nape of the neck with two fingers, and in this way, after many repeated attempts and the use of great force, gradually delivered the shoulders through the os and finally over the perineum.

Levret's hook is also used to remove the head after decapitation. To remove single bones, bone forceps such as Boer's (Fig. 126 *a*) are used. Instead of the cranioclast, Mesnard's forceps as improved by v. L. Winckel, Sr. (Fig. 126 *c*) may also be used in craniotraction.

Necessary Conditions.—The pelvis must not be so greatly contracted that the trunk cannot pass [see § 8, conjugata vera 2½ in. (6.5 cm.) or at least 2⅛ in. (5.5 cm.)].

Indications.—1. When the child is dead or in great danger of dying, and it is unadvisable to expose the mother to the risk of injury by the evolution of a full-sized fetus.

2. In the living child, when there is a relative indication for Cesarean section; that is to say, when the child is so large that it cannot pass the pelvis, and the mother refuses Cesarean section (compare § 33).

§ 25. Embryotomy (Decapitation, Exenteration, Figs. 118, 122, 126 *d*).

Decapitation is performed with Braun's hook (Fig. 122) or with B. S. Schultze's curved knife (Fig. 126 *d*) or with the long curved scissors of Siebold.

Necessary Conditions.—Conjugata vera 2¼–2½ in. (5.5–6.5 cm.) (compare § 8), and the os sufficiently dilated to admit the hand easily.

Indications.—If the fetus is more than seven months old, in transverse or breech presentation (compare § 20, II.). Distention of the lower uterine segment, contraction-ring 2–3 in. (5–7.5 cm.) above the symphysis. Double monsters.

Method.—The hook, protected by the first and second fingers of the left hand, is applied to the neck from the dorsal side. After moderately strong traction on the presenting arm the instrument is then slowly and steadily twisted about its longitudinal axis until the vertebral column is divided. The curved knife is applied and used with a sawing motion. Siebold's scissors are

introduced between two fingers and worked with short clips. The head is then expressed or removed with Levret's hooks or the cranioclast, pressure being applied at the same time through the abdominal wall.

Exenteration or evisceration is performed with a perforator shaped like scissors, or with Siebold's scissors. This method is resorted to when it is impossible to reach the fetal neck, when the abdomen is distended by cystic kidney or other tumors, and in double monsters. Conditions and indications the same as for decapitation.

It is rarely necessary to remove the extremities when they interfere with embryotomy. Cleidotomy is performed when the shoulders obstruct the passage of the fetus.

CHAPTER II.

PURELY OBSTETRIC OPERATIONS ON THE FETUS AND OVUM DURING LABOR.

We have so far considered the preliminary operations. The operative termination of labor can be effected in three ways:

1. By imitating the natural expulsive forces; that is to say, by pressure from above through the abdominal walls. This is the method which involves the least amount of pain and risk to the mother, because the introduction of germs into the interior of the uterus is avoided. Unfortunately, it is not always successful. The method includes Kristeller's, Wigand-A. Martin-v. Winckel's, and Credé's manipulations.

2. By exerting traction on parts presenting exteriorly or low down in the vagina, as for instance on the umbilical cord; by elevating the head after it is born in order to extract the shoulders—Veit-Smellie's method and others.

3. By applying manual or instrumental traction directly from within to the presenting part, for instance forceps, craniotraction, insertion of the fingers into the groin in breech presentations; manual separation of the placenta.

Each of these methods is more dangerous than the preceding one, and it is important in every case to comply strictly with the indications and try each of the methods in succession.

EXTRACTION OF THE LIVING CHILD.

§ 26. **Expression by Pressure on the Abdominal Walls.**

(*a*) Of the trunk, after Kristeller (compare §§ 1 and 4. Figs. 13 and 110).

(*b*) Of the aftercoming head, after Wigand-A. Martin-v. Winckel (compare § 4, Fig. 72), and the analogous correction of the engagement of the aftercoming head in the superior strait (compare § 18).

(*c*) Of the aftercoming head, after Ritgen-Fehling and Smellie-Ritgen (compare § 1, Figs. 10 and 11).

(*d*) Of the placenta after Credé (compare § 1, Fig. 18).

§ 27. **Manual Extraction.**

A. In Breech Positions (Figs. 65, 67, 68).

1. In normal breech positions.
2. In artificial breech positions after version.

The latter is followed by immediate extraction only when there is imminent danger.

Necessary Conditions.—1. The os must be completely or almost completely dilated, otherwise the cervix will be torn or the head become arrested.

2. The membranes must be ruptured.

3. There must be no serious obstacles in the soft or bony parts of the parturient canal.

4. One hip must be easily reached.

Indication.—Danger for mother or child (heart-sounds persisting below 100 or over 160); discharge of meconium from pressure on the cord; asphyxia (the accumulation of CO_2 tends to stimulate the ganglia which control peristalsis).

Method.—The woman is laid across the bed (compare

§ 24). She should be anesthetized if the genitalia are sensitive or narrow.

The index finger of the same side is applied to the anterior groin, the thumb pressed firmly on the ilium and sacrum, while the middle finger steadies the thigh so as to prevent abduction and luxation or fracture. With the other index finger the posterior groin is seized as soon as possible, or the latter may be sought for first (Fig. 67).

If the attempt to hook the index finger into the groin fails, resort must be had to a fillet or strip of iodoform gauze introduced by means of an elastic catheter provided with a mandril (Fig. 68). The blunt hook is dangerous and should be used only when the child is dead.

After the breech is born, the thighs must not be drawn down, as this might easily lead to fracture. They will slip down of their own accord (Fig. 55) as soon as the trunk is raised or lowered. For the remainder of the method, see under Footling Position.

B. In Footling Positions (Figs. 44, 45, 62–64, 69–71, 87–91).

Necessary Conditions and Indications.—The same as for breech presentations. It is to be borne in mind that the prognosis is more unfavorable in footling presentations.

Method.—If both feet present, they should be seized in such a way as to keep the back presenting to the side and slightly forward (Figs. 44, 45). As soon as the knees have reached the vulva, we know that the breech has entered the pelvic inlet. The thighs are then seized and the hips are brought down into the vulva by appropriate movements of elevation and depression (compare Figs. 62 and 63).

If only one foot presents (Fig. 87), it should be seized by the same hand, with the thumb applied along the tendo Achillis, the index finger over the dorsum, and the middle finger under the plantar surface. The back must always be directed forward and to one side, even

when the posterior foot has descended. If the breech is above the pelvic inlet, and the knee therefore has not appeared in the vulva, the other leg may be brought down (Fig. 91), especially if the posterior leg is already within the vagina.

The leg is drawn down until it is possible to hook (Figs. 88, 89) the finger into the groin of the other side (Fig. 90). The breech is then delivered in the same way as above.

The fetal pelvis is then seized with both hands, the thumbs being placed on the iliac bones on either side of the sacrum (Fig. 45), and the trunk is extracted until the angles of the scapula come into view (Fig. 69). The umbilical cord should be pulled down gently so as to loosen it. If it is between the child's legs, it must be pushed back over the leg and hip (Fig. 62).

Now begins the delivery of the arms; the posterior arm is seized like a pen with the thumb and two fingers and brought down by sweeping it across the face and breast (Fig. 70). It should not be drawn directly downward. The anterior arm must then be freed while it is in the hollow of the sacrum, where there is plenty of room. To do this, the fetus is rotated through one-fourth of the periphery at the pelvic inlet by carrying the fetal back past the symphysis from the anterior extremity of one diagonal to that of the other. If, during this procedure, the arm glides behind the occiput, the fetus is rotated through three-fourths of the periphery; that is to say, the back moves past the sacrum. These rotations are possible only after the arm and head have been freed, which is accomplished by pushing the fetal trunk directly upward into the uterus (Fig. 71) and then rotating it, the child being held in both hands, with the thumbs on the scapulæ. To determine whether the arm has been properly freed and rotated, we note whether the fold at the scapula has disappeared. If the anterior arm presents low down with the elbow, it can be safely drawn directly down behind the symphysis. To prevent the

arms from slipping up on either side of the head, the fundus of the uterus is firmly seized between labor-pains (E. Martin, Pinens).

C. Extraction of the Aftercoming Head.

For Veit-Smellie's (Mauriceau-Lachapelle) method, see § 4, Figs. 73, 74. Only moderate force should be used, as undue stretching and slight lesions of the spinal cord are followed not rarely by fatal functional disturbances, not to mention the danger of laceration of the vertebræ and hemorrhage into the vertebral canal. (Wigand-A. Martin-v. Winckel's method of expression and extraction has already been referred to.) The best results are obtained by a combination of both methods. If in breech presentations the back is posterior and the head has reached the pelvic outlet, the modification of Veit-Smellie's method given in § 18 is employed.

D. Shoulder Extraction (compare § 1, Figs. 13 and 110).

This, strictly speaking, includes separation of the placenta by gentle traction on the umbilical cord (§ 1).

§ 28. Instrumental Extraction.

FORCEPS.

Historical.—The forceps was invented about the middle of the seventeenth century by an Englishman named Chamberlen. Palfyn revealed its secret in 1723 to the Academy of Paris. Levret gave the instrument a pelvic curve in addition to its cephalic curve, and invented the so-called French lock, consisting in a thumb-screw fitting into a hole in the other blade (difficult to lock).

Smellie invented the English lock, which is closed by one blade fitting into a notch on the other.

The most important improvements were added by German obstetricians toward the end of the eighteenth and beginning of the nineteenth centuries. In 1796 Busch designed the cross-pieces or shoulders below the lock, to give a firmer hold and facilitate extraction. In 1802 Brünninghausen invented the German lock, which is in use at the present day. The *left* (lower or male) blade is provided with a plate which fits into a slot on the right (upper or female) blade. Naegele gave to the forceps in use at the present day its lightness of construction.

Tarnier and Breus constructed the axis-traction forceps for use when the head is high up in the pelvis. In this instrument,

traction is applied directly to the blades instead of to the handles.

Use and Functions.—1. Traction; pressure is to be avoided on account of the danger to skull and brain.

2. Dynamic effect; assists abdominal pressure and stimulates it by reflex irritation.

3. By leverage so as to assist the two normal rotations: (1) About the lesser oblique diameter of the head (the lesser fontanel moves forward); (2) about its transverse diameter (lesser fontanel rotates around the symphysis). Rocking movements should be employed with great caution and only from side to side.

Necessary Conditions.—1. The os must be fully dilated, or in multiparæ very nearly so. 2. The membranes must be ruptured; that is, they must not be included in the grasp of the forceps. 3. The head must have engaged in the true pelvis with its largest diameter in the interspinal line; in occipital presentations the frontal eminences, in face presentations the parietal eminences, must be at the level of, or below the iliopectineal line. The head is then in the proper position for the application of forceps and in its normal presentation. 4. The head must be neither abnormally large nor abnormally small—diameter of the forceps $2\frac{3}{4}$ in. (7 cm.); hydrocephalus or immature fetus. 5. Absence of pelvic contraction—conjugata vera not less than $3\frac{1}{4}$ in. (8 cm.); compare § 8.

Note.—When the head is high, the forceps should not be used on account of the danger of crushing the soft parts and killing the child. A difficult forceps operation should never be employed unless the child is alive, as perforation involves less danger to the mother.

Indications.—In cephalic positions forceps delivery is indicated whenever, with the above conditions, there is danger for either mother or child.

A. Protracted Labor.—The forceps should be applied only when dangerous symptoms develop, as the diminution in the labor-pains which follows a sudden delivery is apt to produce atony and hemorrhage. For this reason ♏xv (0.1 gm.) of ergotin should be injected before the operation.

(*a*) Primary diminution in the labor-pains.

(*b*) Secondary diminution in the labor-pains; that is to say, the uterus at first contracts vigorously, but owing to some obstacle it subsequently becomes fatigued. Morphine should first be tried.

B. Dangers to the Mother.—(*a*) General conditions:

1. Acute anemia (by premature separation of the placenta, rupture of a varicose vein, or collapse).

2. Stupor, delirium, acute psychoses.

3. Eclampsia.
4. Marked dyspnea, disease of the heart and lungs, struma.
5. Fever above 101.4° F. (38.5° C.).

(*b*) Local conditions:

1. Threatened rupture of a varicose vein; acute edema of the vulva.
2. Purulent or gangrenous inflammation of the uterus and adnexa, as after a protracted labor.
3. Irreducible or incarcerated hernia.

C. Dangers to the Child.—Impending asphyxia, diminution of the heart-sounds during the intervals between labor-pains down to 100, or persistent acceleration to above 160.

Causes.—1. Persistent deep position of the head (diminution in the size of the uterus). 2. Premature separation of the placenta. 3. Compression of the umbilical cord, as in prolapse. 4. Excessive pressure on the brain, as in contracted pelves.

Technic:

I. In Cephalic Positions.

1. Vertex presentation, when the head is low and has completed or nearly completed its rotation (Figs. 99–101, 105, 106–110). Sagittal suture in the anteroposterior or oblique diameter.

As the blades of the forceps are to be applied to the sides of the head, they are always introduced in the transverse or oblique diameter of the pelvis. The introduction of the forceps is best shown in the above figures and the accompanying text. The concavity of the pelvic curve of the forceps must always be directed toward the part which is to descend (lesser or greater fontanel, or chin in vertex or in brow or face presentations). The tip of the forceps should correspond with the base of the skull. The forceps in these three positions follows the normal rotations of the descending and rotating head.

2. When the head is transverse and low in the pelvis, sagittal suture in the transverse diameter. The forceps is applied in the oblique diameter of the pelvis directly—that is to say, without rotating the anterior blade. The concavity of the pelvic curve of the forceps is directed toward the occiput; rotation of the anterior fontanel forward during traction (compare § 11). The blades of the

Plate 12.

Manual Extraction of the Placenta.—The spontaneous separation of the placenta took place according to Duncan's mode (compare page 27); the upper margin remained adherent from the orifice of the right tube to the fundus uteri (due to hemorrhages produced apparently by over-exertion and nursing of a sick relative between the third and fourth months). Separation is effected by a scraping movement of the fingers, using the lateral edges, not the nails, the uterus being stimulated to contraction both before and during the operation by kneading movements with the external hand, so as to enable the operator to distinguish more easily between the soft tissues of the placenta and coagula, and the uterine muscle.

Plate 13.

If the operation has been successful and the placenta is completely detached, the traction of the walls of the uterus behind the hand is clearly felt as the latter is withdrawn, the uncontracted lower uterine segment still accommodating the hand with the placenta and blood-clots. Great care is necessary to remove the blood-clots, as well as any portions of the placenta that may have become separated from the body.

forceps are then loosened and reapplied in the transverse diameter of the head. The forceps is to be used only when immediate termination of labor is indicated.

3. When the head is high in the pelvis, sagittal suture in the transverse or oblique diameter. The forceps is applied only in the diagonal (Breus' axis-traction forceps should be used). Both blades are introduced into the hollow of the sacrum with the handles well depressed, as in position I. (compare Figs. 103, 104, 111), so as to bring the tip of the forceps high up. Before introducing the forceps, the head should be pressed down as far as possible, so that the promontory cannot be reached with the finger, because the sagittal suture has moved to one side and the lesser fontanel has rotated downward and forward. As the head descends, the forceps should be loosened so as to allow the head to rotate. If the head persists in its transverse position till it reaches the pelvic floor, the forceps should still be applied each time in the oblique diameter.

Note.—If the head is freely movable and the frontal eminences are above the iliopectineal line, the forceps

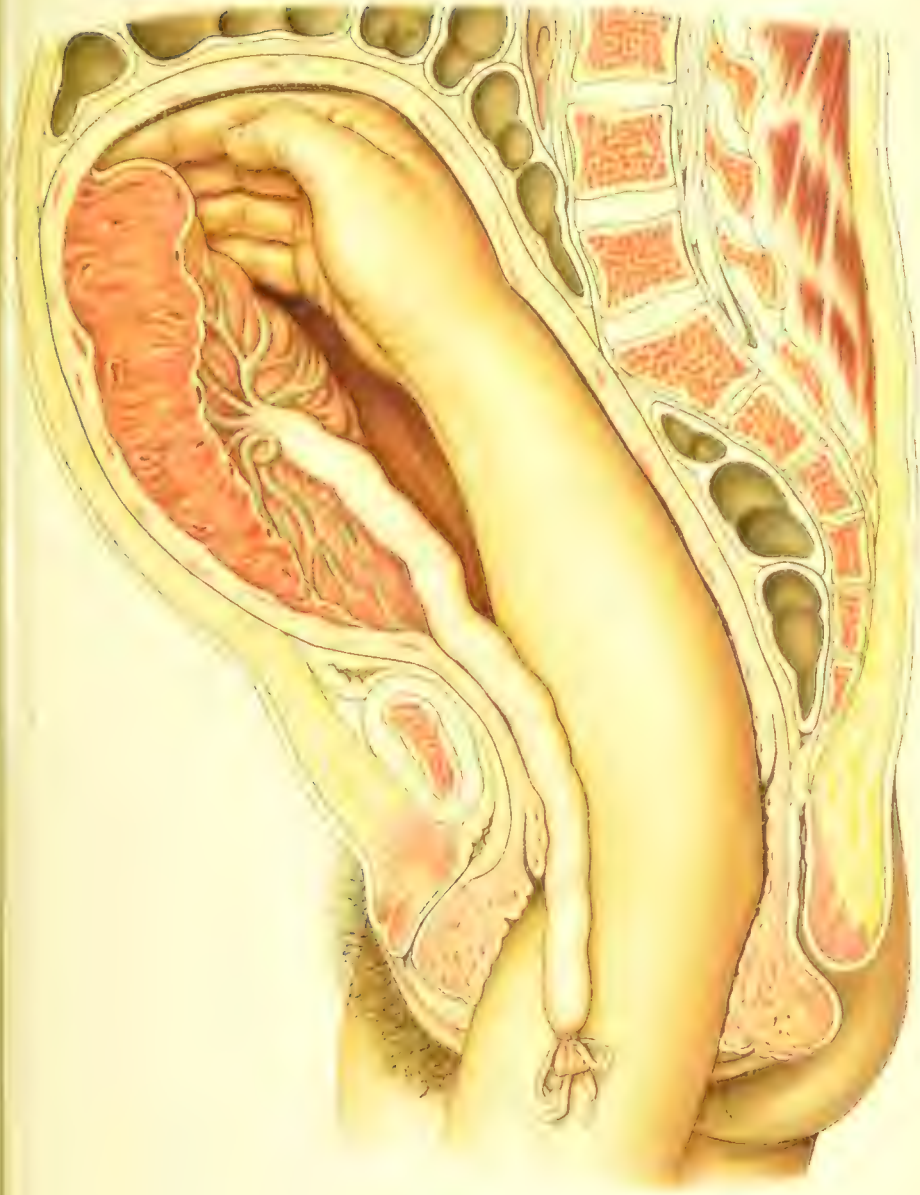

Lith. Anst. F. Reichhold, München

should never be applied. If the child is dead, it is best to wait. In contracted pelves the efficiency of the forceps may be increased by placing the woman in Walcher's position (§ 4).

If the vulva is rigid or very narrow, as in primiparæ, and there is danger of a large perineal laceration, the blades of the forceps must be removed as soon as the greater fontanel or the brow appears at the frenulum perinæi. During the removal of the forceps the perineum must be supported and the head held back with the thumb.

4. In presentation of the anterior fontanel, the head is seized in the transverse diameter and drawn downward (position I.) until the brow appears below the symphysis. The handles are then forcibly raised into position III. (compare Figs. 112–114) and the greater fontanel and face delivered under the symphysis in a horizontal direction (position II.).

If the brow impinges on one pubic ramus (§ 13) the head must be pushed back and turned toward the side corresponding to the face, after which it is brought down in an oblique direction from the opposite side in positions I., II., III. (Kehrer). In this way the brow in Kehrer's *first* presentation of the anterior fontanel (back to the right) describes a ⅂, in the II. a Γ.

II. In Face Presentations.

The forceps must never be applied when the head is above the inlet and the presentation may still be corrected or version performed; it is indicated only when the parietal eminences have passed the pelvic inlet and the chin is anterior.

1. When the face is low in the pelvis and has nearly or quite completed its rotation: vertical line of the face in the anteroposterior or oblique diameter of the pelvis. The forceps is applied to the transverse diameter of the head. Traction downward to position I. until the chin emerges below the symphysis—taking care, however, to

close the handles in position II. and to bring them immediately into position I., so as to depress the chin. Finally the forceps is brought into position III., so as to deliver the occiput over the perineum (see Figs. 115–117).

2. When the face is low in the pelvis and transverse, with vertical line of the face in the inter-spinal line. The forceps is applied in the oblique diameter, with the concavity toward the chin during traction.

III. In Extraction of the Aftercoming Head in Breech Presentations.

The fetal trunk is elevated and the forceps applied in the transverse diameter of the pelvis. Traction is made backward and downward (position I., Fig. 118), and, as soon as the head appears at the pelvic outlet, the handles are elevated. The forceps is rarely used in this condition. It is indicated when the occiput is directed posteriorly and the mouth cannot be reached for the purpose of performing Veit-Smellie's or Wigand-A. Martin-v. Winckel's method, or when these methods fail in spite of Walcher's position (compare § 4). This occurs particularly in funnel-shaped pelves ($3\frac{1}{4}$ in. or 8 cm. as the limit of the distance between the tuberosities of the ischium). It is to be remembered that only moderate force is permissible. The forceps should never be applied when the head is high in the pelvis.

EXTRACTION WITH THE BLUNT HOOK OR WITH THE FILLET (compare § 27 A and Fig. 69).

§ 29. **Manual Extraction of the Placenta** (compare § 1. Plates 12 and 13, Fig. 19).

EXTRACTION OF THE CHILD AFTER IT HAS BEEN CRUSHED (compare §§ 26 and 27).

§ 30. **Extraction with the Craniotractor, Bone-forceps, or Sharp Hook** (compare §§ 24, 25).

GROUP II.

Surgical Obstetric Operations on the Mother.

CHAPTER I.

INDUCTION OF ABORTION AND PREMATURE LABOR.

§ 31. Methods and Indications.

1. Dilatation and preparation of the cervix. Mechanical dilatation with the hystereurynter, colpeurynter, laminaria or tupelo tents, and tampon (iodoform, itrol, or nosophen gauze).

2. Induction of labor-pains; separation of the ovum. Thermal irritation—hot douches, 116°-122° F. [37° to 40° R.], or alternate hot and cold douches, 43°–54.5° F. [5°-10° R.]; electric irritation (constant current); chemical irritation (glycerin tampon); mechanical irritation (bougie, catheter or sound, perforation of the ovum, tamponade of the vagina).

Most stringent antiseptic and aseptic precautions must be observed in all these methods. The vagina and cervical canal are thoroughly irrigated and wiped out. Iodoform, itrol, or nosophen gauze must be sterilized in steam. Laminaria and tupelo tents are preserved in concentrated solution of iodoform, in ether, or in alcoholic solution of salicylic acid (concentrated), or they may be sterilized immediately before their introduction by boiling in a 5 per cent. solution of carbolic acid or a 1 per cent. solution of lysol from two to five minutes.

The *induction of abortion* during the first two months requires two sittings. After the above-described preliminary measures the cervix is first dilated by introducing laminaria tents and allowing them to remain in place from two to six hours. A speculum is introduced and the anterior lip of the cervix fixed with a tenaculum (Fig. 126 *g*). A tampon introduced into the vagina keeps the tent in place. At the end of twenty-four hours the ovum or what remains of it is removed with the finger or with the curet; if a serotinal placenta has already formed (beginning of the fourth month), it is removed with the hand. In some cases the ovum can be expressed

from the uterus by practising Credé's method and pressing two fingers against the body of the uterus in the vaginal fornix (Höning). It is to be remembered that after the dilatation of the cervix or after the administration of ergot the ovum is not infrequently expelled *in toto*, especially after the third month, and that the retention of the decidua alone is not in itself injurious. After the operation a tampon is introduced and allowed to remain twenty-four hours. The patient is kept in bed eight days, and the vagina irrigated daily.

Indications.—1. Absolute pelvic contraction (the shortest antero-posterior diameter 2¼ in. (5.5 cm.) or less). 2. Tumors obstructing the lumen of the pelvis, when they cannot be extirpated, reduced in size, or pushed to one side; this indication is extremely rare, with the exception of carcinoma of the uterus. 3. Irreducible displacements of the uterus (as a result of bands of adhesion, sometimes combined with purulent foci). 4. Multiple myxoma of the chorionic villi (hydatid mole).

To *induce premature labor* it suffices, as a rule, to bring on labor-pains, although in some cases the cervix must at the same time be artificially dilated. This method, which imitates the natural process of parturition and tends to leave its completion to the woman's natural expulsive forces, is the only proper one after the fourth month. Before that date, however, it is often impossible to remove all the structures of the ovum without further interference.

To bring on labor-pains and at the same time dilate the cervix, the latter is packed with iodoform, itrol, or nosophen[1] gauze, saturated in glycerin, or dilatation is effected by hystereurysis. To induce labor-pains without dilating the cervix, we insert a closed elastic bougie (sterilized for several hours in carbolic acid) between the

[1] The author has had a special kind of non-draining gauze prepared by Evens and Pistor, manufacturers of surgical dressings in Cassel. This gauze may be used with advantage in postpartum hemorrhage and in the induction of premature labor, as it does not lose its elasticity and does not absorb blood, thus retaining its efficiency longer than ordinary iodoform gauze, which becomes useless for this purpose after a few minutes (see *Münch. med. Woch.*, 1896, No. 40. Paper read before the Frankfurter Naturf. Versamml.).

ovum and the anterior uterine wall (Krause's method). If this fails, the membranes must be ruptured (Scheel's method, § 22).

A thin-walled, violin-shaped uterine dilator of india-rubber (Barnes, Tarnier, Fehling) may be introduced in the same way as a bougie, filled with sterilized water, and fastened after Mäurer-Dührssen's method, in such a way as to act both as a dilator and as a tractor. If the labor-pains cease after the tampon has been expelled, the uterine contractions may be excited by means of alternate hot and warm douches, at least five liters of boiled water being injected under low pressure at intervals of one or two hours.

Whenever possible, labor should then be allowed to terminate spontaneously. Premature labor should always be induced after the thirty-fourth week, if possible.

Indications.—1. Pelvic contractions according to the following rules: Conjugata vera 3¼ in. (8 cm.) in the thirty-fifth week, 3–3¼ in. (7.5–8 cm.) between the thirty-third and thirty-fourth weeks, 2¾–3 in. (7–7.5 cm.) between the thirty-first and thirty-third weeks, 2⅝–2¾ in. (6–7 cm.) before the thirtieth week. If the conjugata vera measures less than 2¾ in. (6 cm.), the induction of abortion is usually necessary. It may be mentioned that it is possible in many cases, by putting the woman on appropriate diet, cutting down fats and fluids after Prochownik, to reduce the weight of the fetus at term; such a course of feeding must, however, be instituted early.[1] 2. *Placenta praevia* with alarming hemorrhage. 3. Habitual death of the fetus at a certain period. 4. Hydramnion, with dangerous consequences to the mother (high position of the diaphragm).

CHAPTER II.

SURGICAL METHODS OF DILATING THE PARTURIENT CANAL.

§ 32. Episiotomy, Incision of the Portio Vaginalis and Vaginal Fornix. Accouchement Forcé.

[1] The author has found that if the mother weighs less than 120 pounds (55 kgm.), the children are, on the average, lighter and increase less rapidly in weight (*Arch. f. Gyn.*, 1896).

Plate 14.

Cesarean Section.—After the abdominal cavity has been opened and the uterus drawn out, a longitudinal incision is made in the anterior wall, taking care not to injure the child, as the wall is often extremely thin. The incision is carried down to the contraction-ring—that is to say, to the lower uterine segment, which is poor in muscle-fibers. The upper and lower angles of the abdominal wound are closed with several sutures as soon as the uterus has been lifted out. An assistant meanwhile holds the abdominal walls firmly with both hands, so as to prevent the escape of intestines. An elastic ligature may be applied about the lower uterine segment.

1. Episiotomy consists in making lateral incisions in the perineum, opposite the tuberosities of the ischium, $\frac{3}{8}$–$1\frac{1}{4}$ in. (1–3 cm.) in length and $\frac{3}{8}$ in. (1 cm.) deep, by means of a guarded knife (episiotome) or Cowper's scissors (see Protection of the Perineum, in § 1). If there is no reason to anticipate a complete tear into the rectum, episiotomy should not be performed, because the incisions do not heal so readily as an ordinary incomplete perineal tear (airol dressing).

2. In Dührssen's method of **incising the vagina and perineum,** the stricture of the vagina is divided midway between the anus and the tuberosity of the ischium, and the levator ani partially incised with Siebold's scissors. The incisions should be $1\frac{5}{8}$ in. (4 cm.) long and $1\frac{1}{4}$ in. (3 cm.) deep, if they are bilateral; if, as is preferable, the incision is unilateral, it must be 2–$2\frac{3}{8}$ in. (5–6 cm.) in length.

Indication.—Rapid delivery with forceps or traction on one foot in primiparæ when the above-named muscles offer undue resistance.

Scars or congenital areas of rigidity are incised in the same way.

In repairing the incisions, the first suture is made to bring down the lateral angle of the wound, which has retracted upward; the vaginal wound is then closed with partially buried catgut, and the lower perineal wound

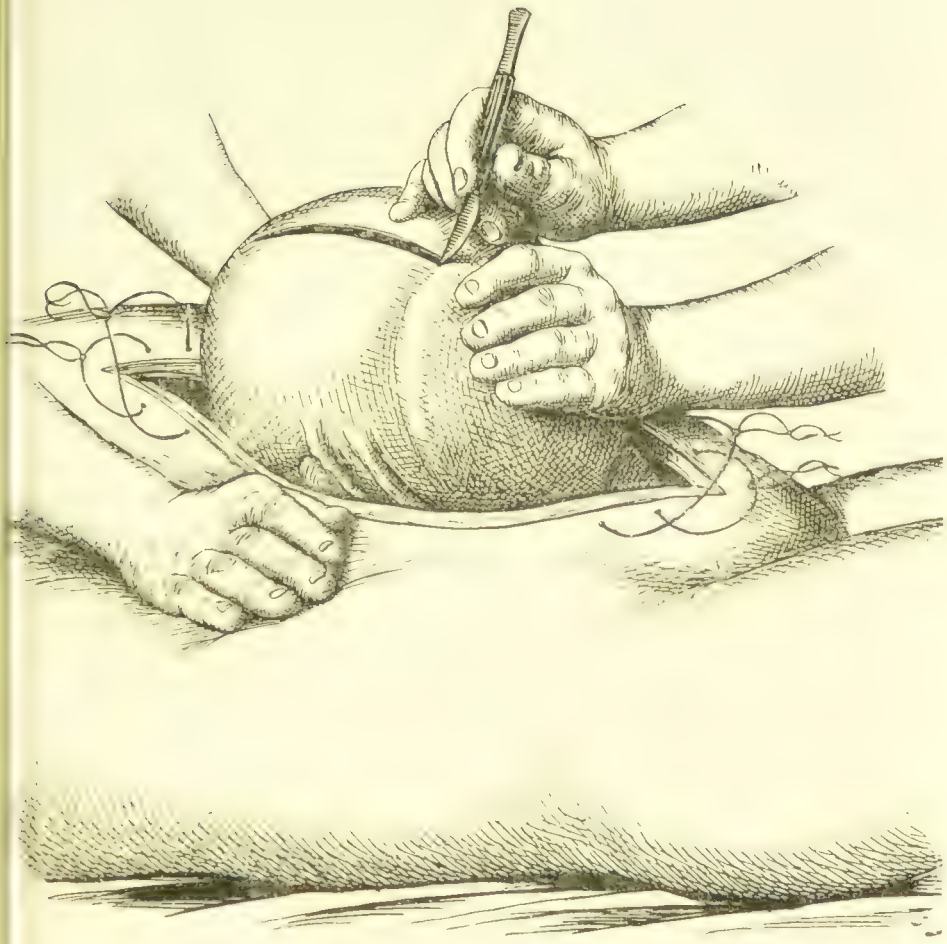

with silkworm-gut[1] sutures, as in plastic perineal operations. The hemorrhage is controlled with hemostatic forceps while the child is being extracted. The wounds may be dressed with airol powder or airol paste.

3. **Superficial and Crucial Incisions in the External Os.**—Rigidity of the os due to loss of its elastic fibers (senile atrophy when the woman is near the menopause; after amputation of the cervix; in luetic and beginning cancerous degeneration). The same procedure is adopted in conglutination or secondary atresia of the external orifice. The tightly stretched portio vaginalis forms a fibrous band about the presenting part; in some cases one-half of the circumference, usually the anterior, fails to dilate. The incisions are made with Siebold's scissors under the guidance of the palpating finger. Occasionally the hemorrhage is quite severe and requires a suture.

4. If there is great danger in delay, several (four) **deep incisions** are made down to the **junction between the portio vaginalis**[2] **and the vagina** (Dührssen-Skutsch). After the anterior, and in some cases the posterior, lip of the os has been fixed with two fingers or with two tenacula, two incisions are made with Siebold's scissors. As this operation is usually performed on elderly primiparæ, it will frequently have to be combined with operation 2.

The *indications* are: Eclampsia threatening the life of the mother when the cervical canal is not sufficiently dilated; premature rupture of the membranes or separation of the placenta with alarming internal hemorrhages. Partial tetanic strieture of the uterus is to be combated with anesthetics. If the cervix is rigid, incisions are contraindicated and Cesarean section[2] must be performed, as the condition is usually due to cancerous infiltration.

5. **Opening of the anterior wall of the cervix** through the vagina and Dührssen's **vaginal Cesarean section**: This operation has become necessary because, in a number of cases of vagino-

[1] I had some non-draining silk made, similar to the non-draining gauze, in order to prevent suppuration and maceration of the stitch-holes (see *Centr. f. Gyn.*, 1896, No. 46).

[2] This, as well as the foregoing operation, must never be performed by an inexperienced operator or one who is not perfectly familiar with its possible results and capable of controlling the untoward consequences which are apt to ensue at any moment. An experienced operator will naturally be inclined to confine its indications within the narrowest limits.

Plate 15.

Cesarean Section; Extraction of the Child.—While an assistant seizes the angles of the uterine wound to prevent its closing prematurely, the operator expresses the breech with one hand and draws out the head with the other inserted into the uterus. If the incision has gone into the placenta, the latter is quickly enucleated and pushed to one side, and the child delivered as rapidly as possible. Some time may elapse before it breathes. If the uterus fails to contract properly after the removal of the placenta and continues to bleed, especially after the elastic ligature has been removed, the assistant compresses the broad ligaments with his two hands and thus constricts the uterine and ovarian arteries.

---

fixation and retroflexion of the uterus after Dührssen's and Mackenrodt's methods, the anterior wall has been unable to keep pace with the evolution of the ovum during pregnancy. As a result, the posterior wall becomes abnormally distended and the portio vaginalis is drawn backward and upward. When labor begins, the presenting part therefore burrows into the anterior portion of the lower uterine segment instead of entering the os: the anterior wall of the uterus bulges into the vagina, and the posterior wall, which now lies above, is subjected to an alarming degree of distention. The round ligaments are found a little above the horizontal rami of the pubis. The os is reached with great difficulty, and, when the attempt is made to bring the anterior lip down, becomes as rigid as if it were made of iron (Strassmann and others). Version is often impossible, perforation difficult, and extraction is possible only after the finger has been introduced into the uterus and the entire anterior septum between the cervix and vagina divided in a longitudinal direction with scissors. To do this, a bivalve speculum is introduced and the anterior lip seized with Muzeux's forceps. If necessary, the incisions may be made as long as 2½–3½ in. (6–8 cm.). The edges of the wound, which are ⅖ in. (1 cm.) in thickness, are temporarily secured with ligatures, each one by itself, and the child is then extracted. After the placenta has been removed, the wound is carefully united, layer by layer. Opening of the anterior peritoneal fold can be avoided by constantly bringing up the raw surface of the vaginal wound as the incision is carried up, and suturing it to that of the uterine wall, under strict antiseptic precautions. Sutures are left long, so as to serve as guides. The posterior uterine wall may be divided in the same way, but it is better in most cases to make the incision in the anterior wall large enough to deliver the child. As the hemorrhage is very profuse, the operation must be completed with all possible speed. The indications for this operation are very few.

CHAPTER III.

DELIVERY OF THE CHILD THROUGH ARTIFICIAL PASSAGES.

§ 33. **Abdominal Section** (celiotomy).

1. **Cesarean Section** (Plates 14–16). Cesarean section is rapidly crowding out perforation and symphysiotomy. As the results of the former operation become more and more satisfactory, there is less necessity to sacrifice the life of the child in order to save the mother.

The *indications*, therefore, are:

1. *Absolute:* When the anteroposterior diameter of the pelvis is 2¼ in. (5.5 cm.) (2½ in. = 6.5 cm.) or less,[1] and the child cannot be extracted *per vias naturales* even after mutilation. 2. Tumors which completely fill the pelvis and cannot be removed. 3. *Relative:* When embryotomy would be possible, but the mother desires a living child. 4. Irreducible hysterocele. 5. Cicatricial atresia of the uterus and vagina, deformity of the uterus, and obstruction of the portio vaginalis after vaginofixation, so that the integrity of neighboring organs would be endangered by a normal labor, or when the obstacle cannot be immediately removed by operative means. 6. Death of the mother. The child continues to live twenty-five minutes after the mother's death.

In cases in which the indication is relative, J. Veit advises the selection of that operation which offers the best chance of the parturient canal remaining aseptic.

Sänger reinstated the old conservative operation of Cesarean section by adopting an antiseptic and reliable method of closing the uterus by suture toward the abdominal cavity. In preantiseptic times the rate of mortality was 54 per cent. and over (Zweifel, Meyer); since the introduction of Sänger's method of closing the uterus, up to 1887, 28 per cent. (Credé); from 1887 to 1889, 8.6 per cent. During the same period the mortality for the induction of premature labor was 2.2 per cent.; for version and extraction, 4.8 per cent.; for perforation, 2.8 per cent. From 1889 to 1892 it was only 6.4 per cent. in Leopold's and Zweifel's clinics together (forty-seven Cesarean sections with three deaths); Leopold has never had a death after perforation, with conjugata vera less than 3 in. (7.5 cm.). Other operators, however, have had a mortality of 14 to 20 per cent. (Sänger's statistics). Perforation, 4–5 per cent.; symphysiotomy, 12 per cent.

These statistics have an important bearing on the prognosis, as

[1] Compare Table, § 8.

Plate 16.

FIG. 1.—**Lines of the Uterine Incisions in Cesarean Section.**—The incisions in general use are the longitudinal incision in the anterior wall of the fundus and the transverse incision in the fundus between the orifices of the tubes, after Fritsch. This has lately come into use and has the advantage of being followed by less hemorrhage. If a longitudinal incision is made in the posterior wall and the wounds suppurate, alarming consequences might result on account of the direct contact with the intestines, which is prevented in the anterior incisions by the presence of the omentum. Kehrer proposed an incision in the lower uterine segment, claiming that the anteflexion which takes place in the puerperium would ensure more perfect spontaneous closure.

FIG. 2.—**Suturing the Uterine Wound.** See text, page 97.

against that of perforation, especially in the eyes of the woman and her relatives, and in connection with Veit's proposition.

Method.—Rigorous antisepsis; two assistants, including the anesthetizer. The operation should be timed to take place before the rupture of the membranes and after the onset of the first vigorous labor-pains (injection of ergotin) (see Plates 14–16).

The abdomen is opened as in any other abdominal operation. The uterus is brought out through the abdominal wound, and the cervix constricted with a drainage-tube the size of the little finger; or, better, with a solid rubber cord, which is to be kept in carbolic acid (Dohrn). The abdominal cavity is then closed with temporary sutures (Plate 14), the uterus opened by a longitudinal incision in the median line down to the contraction-ring or transversely over the fundus between the orifices of the tubes (Fritsch, P. Müller), the ovarian vessels in the adnexa being compressed by the assistant. If the placenta is wounded it is pushed to one side. The assistant holds the upper and lower angles of the uterine wound apart, to prevent the uterus from contracting too suddenly and constricting the child before it is extracted. The membranes are opened and the operator inserts one hand in the amniotic sac and seizes the head, while with the other he delivers the breech from without (Plate 15). The head is then extracted by enlarging the uterine

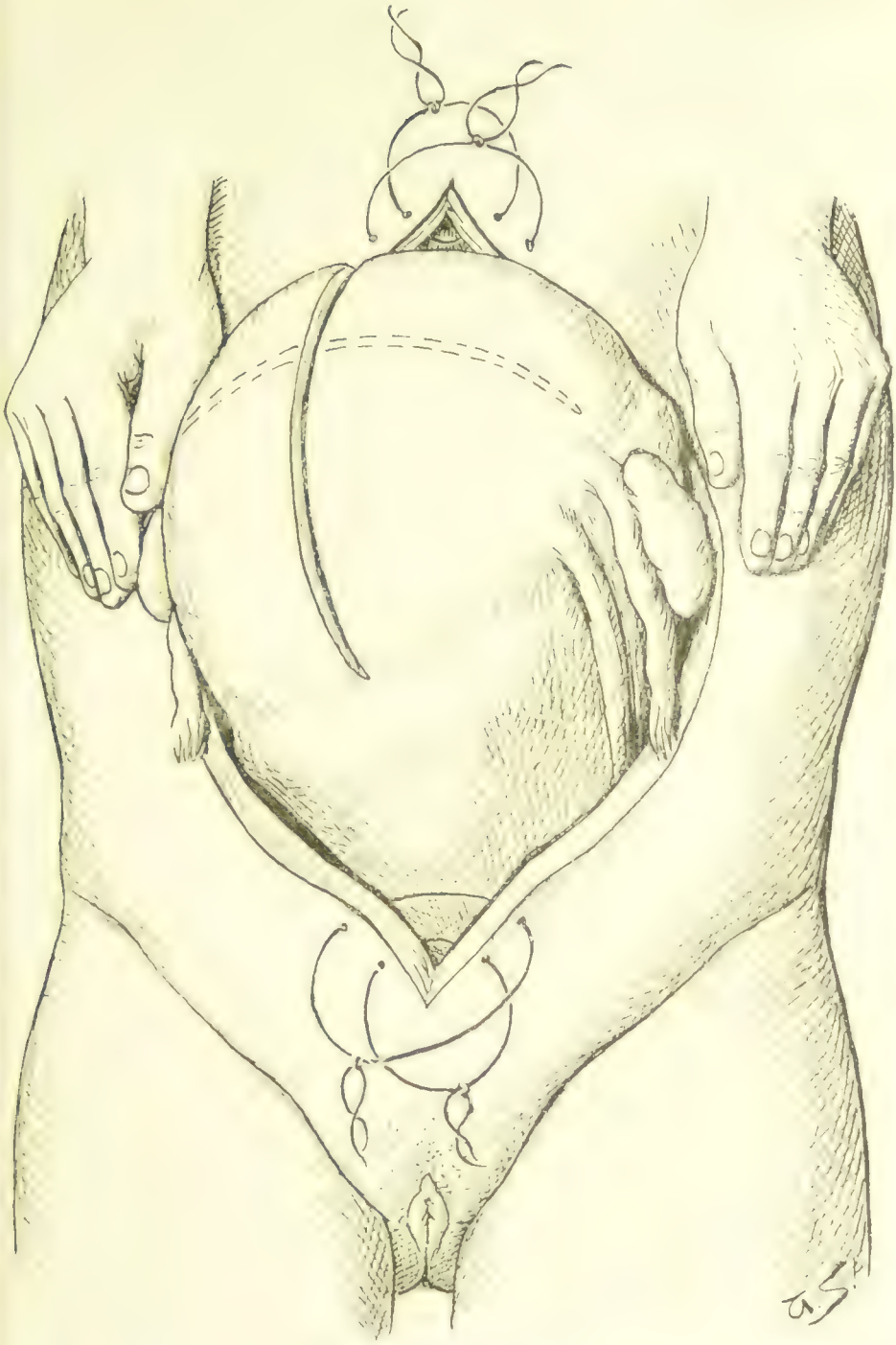

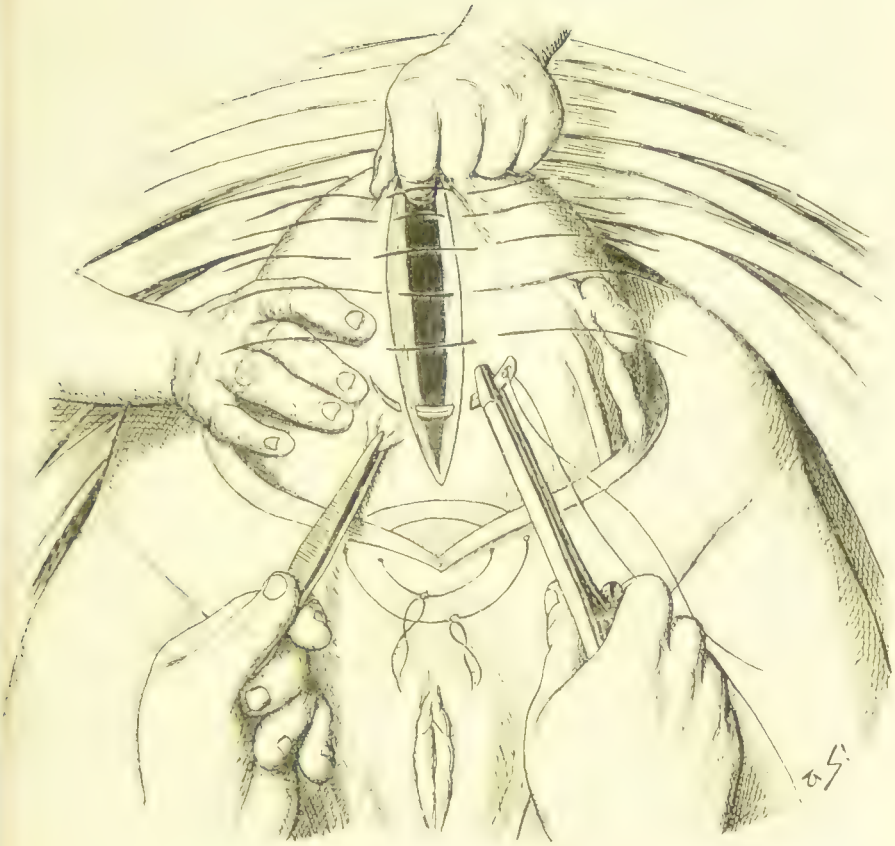

opening if necessary with the probe-pointed knife, the umbilical cord ligated, the placenta removed, and the interior of the uterus disinfected.

The wound, which is about 6 in. (15 cm.) long, is closed as follows (Plate 16): Eight to ten interrupted sutures are introduced through the entire uterine wall and tied, and about ten to twelve superficial Lembert sutures through the peritoneum, which folds in of its own accord.[1] The rubber ligature is then removed, and the atony which now ensues may be combated by first injecting ergotin and placing small pieces of ice into the uterus, or later by introducing an iodoform gauze tampon into the vagina. The next step consists in closing the abdominal cavity, after which the omentum is carefully laid over the uterine wound so as to form adhesions with it and prevent peritonitis, and the abdominal wound is closed.

After-treatment.—Ice-bag to the abdomen, enteroclysis to prevent vomiting, liquid diet. The patient should be kept warm and not be allowed to drink too much; perspiration should be stimulated so as to diminish exudation into the abdominal cavity. For further details, see *Atlas of Gynecology*, under Celio-ovariotomy.

2. **Porro's Partial Hysterectomy by Celiotomy (Supra-vaginal Amputation).**—Extirpation of the uterus above the vagina after the cervix has been constricted with rubber tube or a rubber cord, as in the foregoing operation, or with clamps. The stump may or may not be returned to the peritoneal cavity, or it may be covered with iodoform gauze through the vagina and the vaginoperitoneal wound left open. In this way one of my patients on whom I operated in the country twenty-seven hours after the accident, in spite of beginning fibrinous peritonitis, once recovered after complete rupture of the uterus and escape of the child into

[1] If for any reason it is necessary to complete the operation in a hurry, simple sutures through all the tissues suffice, provided they are closely set and accurately introduced (Fritsch).

the abdominal cavity. If the stump is left outside the peritoneal cavity, its visceral peritoneum is united with the parietal peritoneum at the lower angle of the wound.

Indications.—1. In combination with myomectomy. 2. In septic endometritis, especially when the uterus is ruptured and lacerated. 3. In uncontrollable hemorrhage due to atony of the uterus, when the source of the blood is above the cervix (instead of Cesarean section). 4. When the vagina is absolutely closed by extensive cicatricial adhesions. 5. In ectopic gestation in a rudimentary horn of the uterus. 6. In irreducible hernia uteri gravidi bicornis inguinalis. 7. In severe grades of puerperal osteomalacia.

3. **Celiotomy** in ectopic gestation and incomplete rupture of the uterus with escape of the ovum into the peritoneal cavity.

(*a*) In **ectopic gestation** (compare *Atlas of Obstetric Diagnosis and Treatment*, second edition, § 17 A. under Treatment).

1. When during the first three months of pregnancy the ovum continues to grow in spite of repeated injections of gr. ss (0.03 gm.) of morphine, particularly when the diagnosis is not clear or when violent and alarming symptoms develop. Opening of the vaginal vault and pouch of Douglas is indicated only in the presence of distinct, pedunculated, nonadherent, small tumors.

2. After the first three months of pregnancy, when the amniotic sac is pedunculated.

3. When the sac is not pedunculated and the child is dead, because there is no danger of hemorrhage. The most favorable time is after the sixth month.

4. After rupture of the amniotic sac; but only when the anemia continues to increase and the repeated occurrence of collapse indicates that the hemorrhage has continued, or even when collapse is not very marked and rupture has occurred only a few hours previously.

5. In the case of a living and viable child when the mother is vigorous and external circumstances are favor-

able for the success of the operation and subsequent care of the child. The operation should be performed before the onset of labor-pains.

In all other cases expectant treatment is indicated, partly to wait for the death of the ovum and partly to allow resorption of the child to take place in case of rupture. Ice-bag, sand bag, rest in bed, elevation of the pelvis, opiates. Enteroclysis and hypodermoclysis of salt solution, analeptics. If suppuration takes place, an incision should be made through the vagina and the cavity packed with iodoform, itrol, or nosophen gauze.

The operation is performed in Trendelenburg's posture.

If possible, the sac should be removed through the vagina. This method can be resorted to, however, only when the tubal sac is evidently pedunculated and non-adherent, because unexpected accidents can be dealt with much more quickly and safely in an abdominal operation.

In the case of numerous vascular adhesions, the sac may be left behind in whole or in part. In that case a gauze drain is introduced in the lower angle of the wound, or the sac may be left outside the peritoneum and sutured into the abdominal wound.

It is well to begin by clamping the ovarian arteries and their anastomoses with the uterine vessels. If there is a hematocele, the coagula should, if possible, be removed with their capsule, like a tumor.

(*b*) In **complete rupture of the uterus** (compare *Atlas of Obstetric Diagnosis and Treatment*, second edition, § 20 *a*):

1. *When the child or placenta escapes into the abdominal cavity.*

2. *In uncontrollable hemorrhage*, especially when there are deep intraligamentary lacerations.

The laceration is closed with a conservative suture, and the abdominal cavity drained through the lower angle of the abdominal wound. If the uterine wound is very irregular, especially if it involves the vault of the vagina, or if the woman is in collapse and septic endometritis has

developed, Porro's supravaginal amputation must be performed.

In all other cases, especially in private practice, extraction *per vias naturales* and tamponade of the laceration and of the uterine cavity should be performed. If the hemorrhage cannot be controlled, the cervix is liberated by incisions, Douglas' pouch is opened, the main arteries are clamped or ligated, and a gauze tampon is inserted.

(*c*) In **tumors** (compare *Atlas of Obstetric Diagnosis and Treatment*, second edition, § 21 *d* to *f*).

§ 34. **Symphysiotomy** (Morisani):

Necessary Conditions.—1. The child must be living and viable (heart-sounds good). 2. The mother must be vigorous (no infection). 3. The pelvis must not be ankylosed nor obliquely contracted, nor heart- or kidney-shaped. 4. The soft parts of the parturient canal must be sufficiently dilated. This condition applies only relatively to primiparæ.

Indications.—Contracted pelves with conjugata vera $2\frac{3}{8}$–3 in. (6–7.5 cm.). 2. Presentation of the posterior parietal bone and unfavorable pelvic conditions. 3. Face presentations, chin posterior. 4. Abnormally large child, even when the pelvis is normal. 5. Eclampsia when the fetal head is large. 6. Impending rupture of the uterus.

In general, it may be said that symphysiotomy is performed instead of perforation or when there is a relative indication for Cesarean section—that is, in cases in which premature labor should have been induced after the thirty-third week; but whenever the condition is properly recognized at the right time, premature labor should be induced.

In private practice, symphysiotomy is rarely resorted to; hence first pregnancies, infection, and premature rupture of the membranes constitute a contraindication much oftener than in hospital practice (Leopold).

Rupture of the membranes is to be avoided if possible, and, if it occurs, their function must be replaced by the application of the colpeurynter and injections of mucoid material. Later the vagina and perineum must be incised.

Before proceeding with the operation an attempt may be made to deliver by forceps, and in such cases the forceps is left in place in order to extract the child as rapidly as possible after the symphysis has been divided (Olshausen).

The dangers of the operation consist in the soft parts tearing more than was anticipated and in injury to the urinary organs. Mortality: Symphysiotomy, 12 per cent.; perforation, 4 to 5 per cent.; Cesarean section, 15 to 20 per cent. (Leopold, total statistics).

Technic.—Owing to the physiologic asymmetry of the pelvis, the symphysis is divided a little to the left of the median line and in an oblique direction to the left and downward. The hemorrhage is arrested with gauze compresses.[1] The child is immediately extracted in Walcher's position (§ 4), and, if necessary, the vagina and perineum are incised. The pelvis must be held together by pressure on the two trochanters. After the child is extracted, the symphysis is brought together. The ligaments must be united with sutures, but no sutures are necessary in the bone. In some cases a favorable change in the shape of the pelvis has been observed after symphysiotomy.

If it is desired, silver sutures may be introduced into the bone with the aid of a drill and a spatula behind the symphysis (Schauta), to protect the soft parts. The sutures must remain in place at least three months (Fritsch). Immediately after the operation a firm binder is applied, to hold the pelvis together.

CHAPTER IV.

SURGICAL AND OTHER OBSTETRIC OPERATIONS IMMEDIATELY AFTER COMPLETION OF LABOR.

§ 35. **Primary Repair of Perineal Lacerations and of Injuries or Incisions about the Introitus Vaginæ.**

Sutures for the repair of perineal lacerations are intro-

[1] Compare § 31.

duced transversely, beginning at the anus (compare *Atlas of Gynecology*, § 24), the needle being introduced in sound tissue, carried below the floor of the wound so as to prevent the formation of pockets for the retention of the secretions, and brought out on the other side in sound tissue; or several layers of buried sutures may be introduced. In complete perineal lacerations the rectal mucous membrane is sutured separately with catgut.

If primary union fails to take place in flabby and varicose tissues, all further attempts should be put off until about six weeks after the puerperium, when the laceration is repaired according to the rules of perineoplasty (*Atlas of Gynecology*, § 24). In regard to the possibility of secondary repair, compare *Atlas of Obstetric Diagnosis and Treatment*, second edition, page 253.

Lacerations of the clitoris must be carefully ligated, as they have frequently led to fatal hemorrhage. Tears of the vagina usually bleed very little. They are best united by transverse sutures introduced in the same way as in perineal lacerations. The same remark applies to incisions (see § 32).

§ 36. **Postpartum Operations Performed upon the Portio Vaginalis through the Speculum.**

These operations are called for usually to *control hemorrhage.*

If the operator has plenty of assistance, the woman is placed on her back across the bed or on a suitable table covered with a matress (light, portable operating-tables are now to be had); otherwise she is placed in Sims' position and a bivalve speculum introduced. The portio vaginalis is then brought down with a double tenaculum or Muzeux's forceps applied to the anterior lip of the cervix, which usually lies deep down and immediately behind the tuberculum vaginæ. Rigid antisepsis is imperative.

(*a*) The incisions into the portio vaginalis referred to in § 22, under 3 and 4, rarely bleed so freely as to require sutures. Lateral tears, however, are very apt to extend

into the larger vessels at the side of the vagina and must be carefully sutured, in urgent cases even without exposing the portio vaginalis.

Perforating tears (ruptures) or uncontrollable hemorrhages from deep cervical lacerations must be treated according to the principles laid down in § 33, 3 *b*, and *Atlas of Obstetric Diagnosis and Treatment*, second edition, § 20 *c*.

(*b*) The introduction of the gauze tampon[1] into the vagina and uterus (Dührssen) is employed either for the purpose of packing, or to induce labor-pains, or to provide drainage in cases of rupture. This procedure is always a serious one on account of the danger of introducing infectious germs, and should be preceded by bimanual massage of the relaxed uterus.

It is most frequently employed for the control of hemorrhage due to uterine atony. The operator should remember that either the entire uterus or only that portion of the uterine wall where the placenta was inserted may fail to contract (compare also *Atlas of Obstetric Diagnosis and Treatment*, second edition, § 23, page 273, and § 26, under 7, Metrophlebothrombosis).

Tamponade is best performed through a speculum, as the danger of infection is much increased when the gauze is introduced simply under the guidance of the palpating finger. The strips of sterilized gauze (iodoform, itrol, or nosophen) must be kept in sterile tubes and carried with the dressing-forceps directly to the placental site until the fundus of the uterus is firmly packed, after which the rest of the gauze is inserted, completely filling the uterus and vagina.

The gauze may be saturated with appropriate hemostatic and antiseptic preparations, such as liquor alumini acetatis (20 per cent.), formalin (1 per cent.), sterilized gelatin (5 to 10 per cent.), or ferripyrin (20 per cent.).

If there is any possibility of a deep laceration in the cervix or vault, the operator must make sure that the hemorrhage does not arise from the laceration, in which

[1] See note on non-draining gauze for tampon, § 31.

case it must be closed with a suture. If this is impossible and tamponade fails to arrest the hemorrhage, the procedures mentioned in § 33, 2 and 3 *b*, must be resorted to.

In very profuse hemorrhages due to atony of the uterus, the following means sometimes prove successful:

(*c*) Drawing down the portio vaginalis in front of the vulva with tenaculum forceps, thus arresting the hemorrhage by compressing and stretching the vessels in the ligaments. In addition, the accumulation of CO_2, which ensues from the arrest of the blood-current, and the irritation of the cervical ganglia secondarily excite the uterus to contraction. While the portio vaginalis is slowly and gradually brought down in front of the vulva and remains in that position, it must be covered with sterile gauze compresses.

(*d*) Irrigation of the uterus, with or without removal of the remains of the secundines.

The portio vaginalis is exposed and the uterus is irrigated with a two-way uterine catheter, weak antiseptic solutions, such as 3 to 5 per cent. carbolic or boracic acid, 1 per cent. lysol or metacresol, or 1 per cent. salicylic acid, being used. In irrigating the uterus after an abortion, an apparatus designed by Schultze, which at the same time acts as a dilator, is particularly useful. Rigorous antisepsis must be maintained.

This method is employed in puerperal endometritis, from one to three irrigations being given. It is always a serious operation on account of the reopening of fissures and the injection of fluid into the partially thrombosed vessels of the placental site. Marked rises of temperature are apt to follow. In severe infection of the mucous membrane, especially when a very high temperature persists, the interior of the uterus may be painted with concentrated carbolic acid (compare *Atlas of Obstetric Diagnosis and Treatment*, second edition, under Puerperal Fever).

In unavoidable abortion, induction of abortion, and

retention of secundines, removal of the remains by scraping with the placental forceps or with the hand (Fig. 126, *e*, *f*, *g*) may be supplemented by irrigations (compare § 31).

The vagina need not be irrigated in ordinary labors; but if the asepsis during labor has been doubtful, owing to suspicious examinations by other persons or the presence of inflammation, or if the lochia are persistently bloody and fetid and the after-pains are severe, antiseptic irrigation of the vagina is indicated. Ergot may be administered at the same time.

In hemorrhages due to atony, hot irrigations (36° to 42° R. = 113° to 126.5° F.) are indicated.

In lacerations of the uterus, antiseptic irrigation of the abdominal cavity is not to be recommended.

(*e*) Atmokausis or vaporization has been employed with good success to combat the complication of hemorrhage and gangrene after incomplete abortion. I have used Pineus' apparatus and found it very serviceable, but I would not advise its employment without proper assistance and the necessary preparation, or in dispensary patients; nervous patients should be anesthetized. An application lasting from one-fourth to one-half minute at 105° to 110° R. (268° to 280° F.) is sufficient. Care must be taken to determine the length of the uterus beforehand so as not to perforate the soft uterine wall, and the operator should remember that the organ tends to contract vigorously and thus may impale itself, so to speak, on the instrument. During the operation the intrauterine vaporization catheter must be constantly moved to and fro, so as not to produce too great an effect by contact, as this might lead to stenosis or atresia of the cervix. To guard against the latter accident, the tube at this point should be covered with gauze or celluvert. If the action of the vapor is prolonged and too intense, it is very apt to obliterate the puerperal uterine cavity. Hence the method should be employed only in extreme cases after full-term or premature labor.

INDEX.

Abortion, induction of, 89
Aftercoming head, Veit-Smellie's method of extracting, 37
Vienna method of extracting, 38
von Winckel's method of extracting, 37
Wigand's method of extracting, 37
Amniotic sac, perforation of, 69
Amputation of uterus, Porro's supravaginal, 97
Atmokausis, 105
Attitude, physiologic, 17; Fig. 4
Axis, pelvic, curve of, 16

Bone, occipital, presentation of, 44
Breech presentation, 34; Pl. 8
conversion into incomplete footling, 64
presentations, protection of perineum in, 36
Brow presentation, 49
Busch-Braun's method of version, 74

Canal, parturient, operation for dilating, 91
Caput succedaneum (table), 38
Celiotomy, 98
in ectopic gestation, 98
in rupture of uterus, 99
Cephalic version, 73
Cephalotripsy, 76
Cervix, opening anterior wall of, 93
Cesarean section, 95; Plates 14–16
indications for, 95
Porro's operation, 97
Sänger's operation, 95
vaginal, after Dührssen, 93
Conduplicato corpore. See *Delivery.*
Contraction-ring, Plates 6 and 7
Cord, prolapse of, 65
Cranial positions, 15
Cranioclasis, 77
Credé's method of delivering placenta, 27
solution, 26
Curve of pelvic axis, 16

Decapitation, 78
Delivery conduplicato corpore, 48; Figs. 51–54
Dilatation-stage, duration of, 26
Dilator, uterine, 91

Dolores conquassantes, 22
præparantes, 18
D'Outrepont's method of version, 74
Dührssen's method of incising the vagina and perineum, 92, 93
vaginal Cesarean section, 93
Duncan's mode of separating placenta, 27
Duration of pregnancy, 19
Dystocia, 48

Ear, anterior, presentation of, 52
posterior, presentation of, 52
Embryotomy, 78
Episiotomy, 92
Evolution, spontaneous, 48; Figs. 55 and 56
Exenteration, 79
Expression by pressure on the abdominal wall, 80
External os, incisions in, 93
Extraction, instrumental, 83
manual, of living child, 80, 81
of aftercoming head, Prague method, 37
of child after crushing, 88
of placenta, manual, 27
shoulder, 83
with blunt hook or fillet, 88
Extremities, prolapse of, 67

Face and brow presentations, conversion of, 62, 64
presentation, 32
chin anterior, 31
chin posterior, 50
Fetus and ovum, operations on, 62, 79
Fontanel, greater, descent of, 44
Footling presentations, 52
Forceps, 83
indications for use of, 84
technic, 85–88

Greater fontanel, descent of, 44; Pl. 9, Fig. 27

Head, aftercoming, abnormal mode of escape of, 53; Figs. 92 and 93
Martin's method of extracting, 37
Mauriceau-Lachapelle's method of extracting, 37
methods of extracting, 37, 83
Prague method of extracting, 37
Veit-Smellie's method of extracting, 37
Vienna method of extracting, 38
von Winckel's method of extracting, 37
Wigand's method of extracting, 37
deep position of, 46; Fig. 12
deviations of, 48
"over-rotation" of, 25
rotation of, 21, 23, 28, 29, 36, 37; Fig. 26
in breech positions, 36, 37
Hemorrhage, postpartum, treatment of, 104, 105
Hohl's manipulation, 25

Instrumental extraction, 83

Kristeller's method of delivering the trunk, 26, 37, 78; Fig. 13

Labor, mechanism and management of, 17
onset of, table showing differences in multiparæ and primiparæ, 19
premature, 90
induction of, 90
Krause's method, 91
protection of perineum during, 23, 36
table showing clinical and obstetric course of, 39
table showing presenting part and caput succedaneum in various presentations, 38
Laceration of perineum, primary repair of, 101
Litzmann's obliquity, 20, 42; Fig. 11 in text

Manipulations, Ritgen-Fehling's, 25
Smellie-Ritgen's, 25
Manual extraction of living child, 80, 81
of placenta, 27
Martin's method of extracting the aftercoming head, 37
Mauriceau-Lachapelle's method of extracting the aftercoming head, 37; Fig. 73
Membranes, rupture of, 69
Mother, surgical obstetric operations on, 89

Naegele's obliquity, 20, 40; Pl. 9, Fig. 21; Fig. 10 in text

Obliquities, Litzmann's, 20, 42; Fig. 11 in text
Naegele's, 20, 40; Pl. 9, Fig. 21; Fig. 10 in text
Roederer's, 20
Solayrès', 20, 40; Fig. 24
Obstetric operations, classification of, 59
Occipital bone, presentation of, 44; Fig. 23
Operations, obstetric, classification of, 59
on fetus and ovum, 62, 79
performed postpartum on portio vaginalis, 102
Porro's supravaginal amputation of uterus, 97
postpartum, on portio vaginalis, 102
preliminary, purely obstetric, on fetus and ovum, 62
primary repair of perineal lacerations, 101
purely obstetric, on fetus and ovum during labor, 79
simple obstetric, on fetus and ovum, 62
surgical, for dilating the parturient canal, 91
obstetric, on mother, 89
"Over-rotation," 25

Parturient canal, surgical operation for dilating, 91
Perforation, 76
of amniotic sac, 69

Perineal lacerations, primary repair of, 101
Perineum, laceration of, primary repair of, 101
protection of, during labor, 23
in breech positions, 36
Placenta, Credé's method of expressing, 27
Duncan's mode of separation, 27; Fig. 17
manual extraction of, 27; Pl. 12
mechanism of separation of, 27
prævia, 72; Pl. 11
Podalic version, 69, 74
Porro's operation, 97
supravaginal amputation of uterus, 97
Portio vaginalis, postpartum operations on, 102
Position, breech, I., Pl. 8
face, I., 32; Fig. 8
II., mechanism in, 33
mechanism in I. and II., chin anterior, 32
sinciput, I., mechanism in, 28
II., mechanism of labor in, 30
vertex, I., Plates 3, 5, 6, 7; Fig. 3
II., Pl. 4
II., mechanism of labor in, 28
Positions and presentations, classification of, 12–15
breech, 34
I. and II., mechanism of, 34
rotations of head in, 36, 37
cranial, 15
obliquities of, 39
Positions, oblique and transverse shoulder, 55; Pl. 10; Fig. 48 *et seq.*; Fig. 75 *et seq.*
sinciput, 28
vertex, III. and IV., 28
Postpartum hemorrhage, 104, 105
operations on portio vaginalis, 102
Prague method of extracting the aftercoming head, 37
Pregnancy, duration of, 19
Premature labor, induction of, 90
Krause's method, 91
Presentation, 11
breech and heel, 35; Fig. 9
conversion of, into incomplete footling, 64
brow, 49; Fig. 13
face, chin anterior, 31; Fig. 7
chin posterior, 50; Figs. 40–42; Fig. 8 in text
of anterior ear, 52
of occipital bone, 44
of posterior ear, 52
of sinciput, 49
vertex, 17, 19; Plates 1 and 2; Fig. 3
I., Figs. 1 and 4
II., Fig. 2
Presentations and positions, classification of, 12
face and brow, conversion of, into vertex presentation, 62
and brow, conversion of unfavorable into favorable, 64
footling, 52; Plate 11; Figs. 44, 45, 86–89
Prolapse of cord, 65
of extremities, 67

Ring, contraction-, Plates 6 and 7
Ritgen-Fehling's manipulation, 25
Roederer's obliquity, 20, 44; Fig. 23
Rotation of head, 21, 23, 28, 29, 36, 37; Fig. 26
Rupture of membranes, 69

Sac, amniotic, perforation of, 69
Sänger's operation, 95
Section, Cesarean, 95; Plates 14-16. See also *Cesarean.*
Segmentum chartaceum, 19
Shoulder extraction, 83
  presentations, 55
Sinciput positions, 28
Skull, shape of, in various positions, 38
Smellie-Ritgen's manipulation, 25
Solayrès' obliquity, 20, 40; Fig. 24
Solution, Credé's, 26
Spontaneous version, 47
Supravaginal amputation of uterus, Porro's, 97
Symphysiotomy, 100

Tamponade of vagina and uterus, 103
Trunk, delivery of, Kristeller's method, 26, 37, 78

Uterine dilator, 91
Uterus and vagina, tamponade of, 103
  supravaginal amputation of, 97

Vagina and uterus, tamponade of, 103
Veit-Smellie's method of extracting the aftercoming head, 37; Fig. 73
Version, 70
  cephalic, 73
  combined direct and indirect, 71, 73
    direct internal, Busch-Braun's method, 74
    indirect internal, d'Outrepont's method, 74
  external, Wigand's method, 70
  podalic, 69, 74
  spontaneous, 47; Figs. 57–59
Vertex positions, 28
  presentation, Plates 3, 5–7
Vienna method of extracting the aftercoming head, 38
Von Winckel's method of extracting the aftercoming head, 37; Fig. 72

Wigand's method of external version, 70
  of extracting the aftercoming head, 37

WELLCOME LIBRARY INSTITUTE

EXPLANATION OF THE NUMERALS IN THE ILLUSTRATIONS.

1. Symphysis.
2. Promontory.
3. Coccyx.
4. Cervix.
4 *a*. External os.
4 *b*. Internal os.
5. Bladder.
6. Vagina.
7. Rectum.
7 *a*. Anus.
8. Uterine wall and body of uterus.
9. Spines of the iliac bones.
10. Tuberosities of the ischium.
11. Intact fetal membranes (bag of waters).
12. Caput succedaneum.
13. Fetal head.
14. Perineum.
15. Anterior wall of vagina.
16. Umbilical cord.
17. Placenta.
18. Contracted uterine body.
19. Fetal membranes.
20. External genitalia, rima pudendi.
21. Distended lower uterine segment.
22. Handle of forceps.
23. Blade of forceps.
24. Hook.
25. Fillet.
33. Thigh.
40. Tuberosacral ligament.
44. Sagittal suture.
45. Lesser fontanel.
45 *a*. Greater fontanel.
45 *b*. Frontal bones.

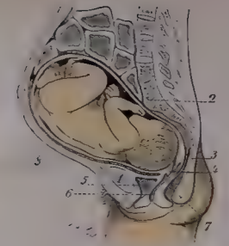

FIG. 1.—Primipara in the last month; vertex position I, occipital presentation. The head is already fixed in the true pelvis; cervical canal completely closed; back to the left, extremities to the right; heart sounds to the left, midway between the umbilicus and the anterior superior spine of the ilium.

FIG. 8.—Birth of the head; extreme outward bulging of the perineum; the head rolls out, as it were, under the lower border of the symphysis. The greatest periphery of the head passes, being the suboccipito-bregmatic (12½ in. = 32 cm.), with the least oblique diameter (4 to 4½ in. = 10 to 11 cm.).

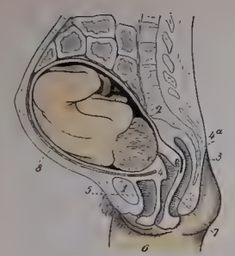

FIG. 2.—Multipara in the last month; same position of the child: Head above the pelvic inlet still movable; internal os closed, external os open.

FIG. 9.—Protection of the perineum during the birth of the head in Sims's position.

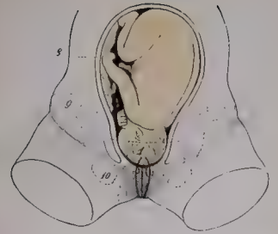

FIG. 3.—Position of the head at the pelvic inlet at the beginning of labor; the sagittal suture in the transverse diameter of the pelvis.

FIG. 10.—Protection of the perineum combined with expression of the head, after Ritgen-Fehling; pressure is applied with the flat of the hand to the child's chin from the sacrum.

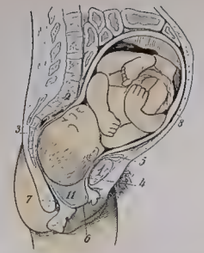

FIG. 4.—Expulsive period (the amniotic sac still intact in the vulva): The sagittal suture lies in the right or first oblique diameter (occiput to the left and in front). The first rotation of the head about its transverse diameter is completed, the chin rests on the chest, the occiput has descended.

FIG. 11.—Protection of the perineum combined with expression of the head, after Smellie-Ritgen; two fingers are inserted in the rectum and exert pressure against the child's chin.

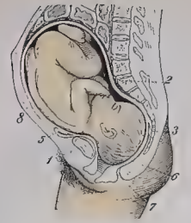

FIG. 5.—After completion of the second rotation about the lesser oblique diameter: Lesser fontanel in front, behind the symphysis. The membranes have ruptured and the amniotic fluid is discharged. The perineum has receded. Caput succedaneum in process of formation.

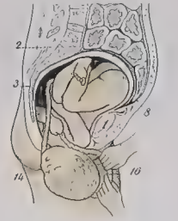

FIG. 12.—In cranial position I. the face, after the birth of the head, turns toward the mother's right thigh; the right shoulder emerges under the symphysis, the left follows over the perineum in the left oblique diameter. When the umbilical cord is coiled once about the neck, as shown in the figure, it must be loosened and stripped back over the head.

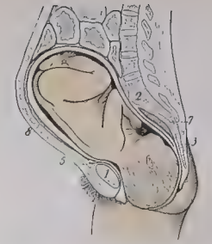

FIG. 6.—Engagement of the head in the vulva, usually in the right oblique diameter, lesser fontanel in front, so that in cranial position I. the right parietal bone (caput succedaneum) first appears below the symphysis. Third rotation of the head about its transverse diameter, the chin moving away from the chest.

FIG. 13.—If the birth of the shoulders is delayed, they must be extracted by hooking the right index finger into the posterior axilla and applying pressure with the other hand to the fetal breech (Kristeller's method).

FIG. 7.—Bulging of the perineum and rectum as the head engages in the vulva.

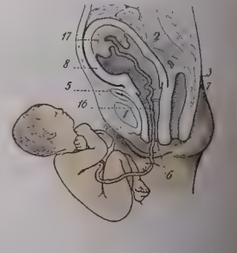

FIG. 14.—The skull shows the characteristic shape of a cranial position. The umbilical cord has been ligated in two places at the umbilicus and immediately below the mother's external genitalia. The separation of the placenta has not yet begun. (Diagrammatic.)

FIG. 15.—The uterus is beginning to contract and to expel the placenta, behind which the retroplacental hematoma is forming. (Diagrammatic.)

FIG. 22.—Presentation of the posterior parietal bone (Litzmann's obliquity) occurs in the following conditions: (a) In normal pelves in one-third of all cases, especially in primiparae; (b) in flat pelves. The sagittal suture approaches the symphysis so that the left parietal bone which is closely applied to the promontory, is the first to enter the pelvic inlet; in other words, it lies deeper and forms the presenting part. The condition is usually associated with descent of the greater fontanel.

FIG. 16.—The placenta has descended into the lower segment of the uterus; the body of the uterus is well contracted and the membranes are reflected over the maternal surface of the placenta.

FIG. 23.—Presentation of the occipital bone (Roederer's obliquity). The head is strongly flexed on the breast, so that the lesser fontanel is lowest and the smallest periphery of the fetal head (12½ in. = 32 cm.), corresponding to the lesser oblique diameter (4 in. = 10 cm.), enters the generally contracted pelvis. Often associated with Solayres' obliquity. (See the following.)

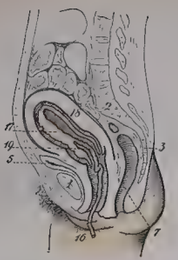

FIG. 17.—Unusual mode of separation of the placenta (after Duncan); a portion of the edge is the first to appear at the vulva. (Schematic.)

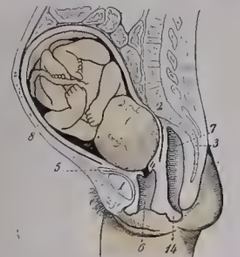

FIG. 24.—Combination of cranial position II (back to the right) and Solayres' obliquity; that is to say, the head has entered the pelvic inlet in the left oblique, instead of in the transverse diameter.

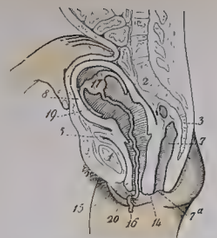

FIG. 18.—Credé's method of expressing the placenta, applied during a labor-pain not earlier than fifteen to thirty minutes after the birth of the child.

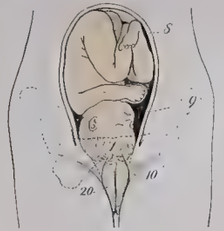

FIG. 25.—Sinciput position II.: Back to the right more frequently than to the left. Usually secondary to a cranial position II., and produced by the occiput slipping backward along the spines of the ischium instead of rotating forward in the true pelvis. Cause. Precipitate engagement of the head in the transverse diameter with violent labor-pains, in pendulous abdomen, or when the pelvis is disproportionately large and the fetal head small. In flat pelves it is combined with presentations of the anterior or posterior parietal bone.

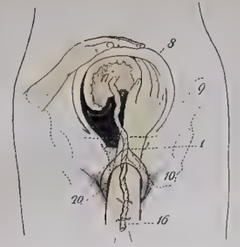

FIG. 19.—Manual extraction of an adherent placenta.

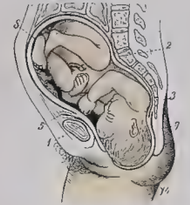

FIG. 26.—First mode of delivery by flexion of the head in sinciput position, so that, when the resistance on the part of the genital canal is abnormally small, the chin during the backward rotation of the vertex remains in apposition with the chest. The lesser fontanel continues to descend, while the greater fontanel becomes arrested at the symphysis. The occiput escapes over the perineum and later the brow under the symphysis (the greatest periphery of the head, the suboccipitobregmatic (12½ in. = 32 cm.), passes, but the larger biparietal diameter is posterior).

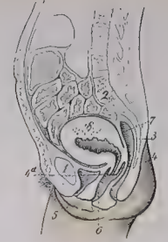

FIG. 20.—Uterus of a puerpera, showing the proper degree of postpartum contraction and anteroflexion.

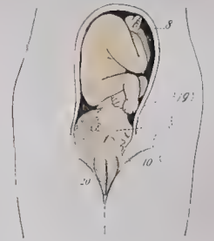

FIG. 27.—Second mode of delivery by extension of the head in sinciput position, and abnormally great resistance on the part of the parturient canal, immediately above the pelvic outlet the brow descends and thus moves away from the breast, after which the anterior rotation of the brow takes place.

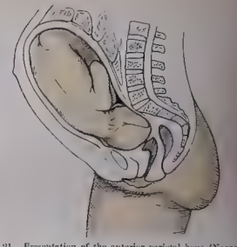

FIG. 21.—Presentation of the anterior parietal bone (Naegele's obliquity) occurs in the following conditions: (a) In normal pelves owing to extramedian position of the head above the pelvic inlet, especially in multiparae; (b) in pendulous abdomen, when the fetal trunk sinks forward so that the axis forms an oblique angle with the pelvic inlet; (c) in flat anteroposteriorly contracted pelves, when the head is forced against the posterior shoulder. The presenting parietal bone glides over the symphysis into the true pelvis, while the posterior parietal bone is pushed upward along the promontory. As a rule, the greater fontanel is lower than the lesser one.

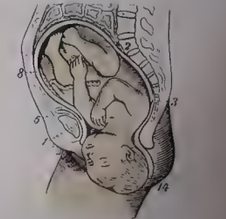

FIG. 28.—The brow finally catches on the symphysis and the occiput escapes over the perineum. The greatest periphery that passes is the fronto-occipital diameter (13½ in. = 34 cm.) with the anteroposterior diameter (4½ in. = 12 cm.)

Fig. 29.—Brow position I. (brow presentation): Engagement of the sagittal suture in the transverse diameter.

Fig. 36.—Descent of the chin, which maintains its position to the right and in front, close to the symphysis. The right half of the face presents (caput succedaneum).

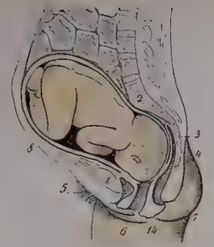

Fig. 30.—As the head descends it presents in the left oblique diameter, brow in front.

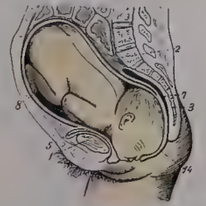

Fig. 37.—Engagement of the head in the vulva: the chin catches on the symphysis, while the face and brow escape over the perineum.

Fig. 31.—The upper maxilla catches on the symphysis. The right frontal eminence, then the greater fontanel, and finally the occiput appear over the perineum.

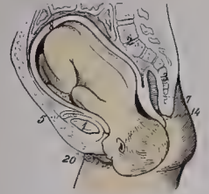

Fig. 38.—The chin again approaches the chest.

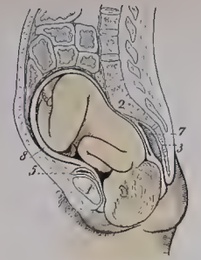

Fig. 32.—The occiput escapes over the perineum.

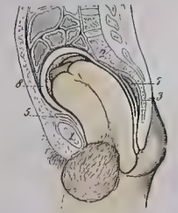

Fig. 39.—After the birth of the head the face turns toward the mother's right thigh, the trunk rotates about its sagittal axis, and the left shoulder appears over the perineum. This is followed by the birth of the trunk and lower extremities in the line of the axis of the pelvic canal.

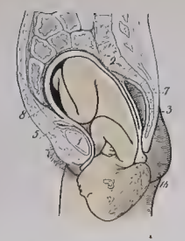

Fig. 33.—The entire head is born, the face and chin escaping under the symphysis. Characteristic shape of the skull in brow positions.

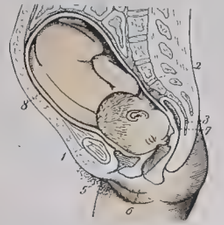

Fig. 40.—Face position I., chin posterior (anomaly of rotation), constitutes an unfavorable presentation. The vertical line of the face is in the first oblique diameter, chin to the right and behind

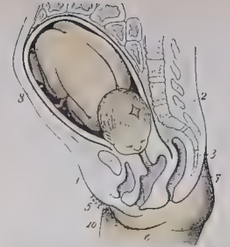

Fig. 34.—Face position I., chin in front. Engagement of the head at the pelvic inlet; vertical line of the face in the transverse diameter; chin to the right, back to the left.

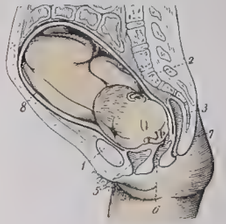

Fig. 41.—Head rotates into the antero-posterior diameter; chin posterior.

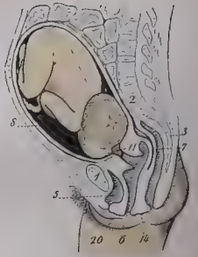

Fig. 35.—Engagement of the head, with the vertical line of the face in the left oblique diameter; chin in front and to the right.

Fig. 42.—Birth of the face, chin posterior. Arm reflected backward; characteristic shape of the skull in face positions. Extreme extension of the vertebral column. This mechanism is possible only in the case of an immature or greatly macerated fetus.



FIG. 43.—Version (combined, direct internal) in face position L: Chin posterior and high; when the head is above the pelvic inlet (forceps contraindicated) and the os is fully dilated, the woman is placed on her right side, corresponding to the part which is brought down. The left hand is introduced.

FIG. 49.—Gradual descent of the presenting right arm.

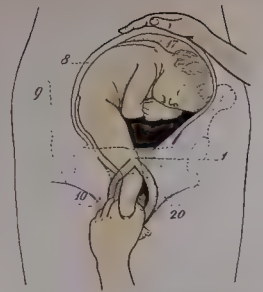

FIG. 44.—Both feet are brought through the vulva and the breech is directed into the true pelvis. Version is completed when the knee appears in the vulva.

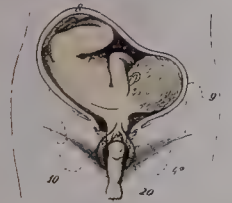

FIG. 50.—Descent of the right shoulder; the head is on the left innominate bone.

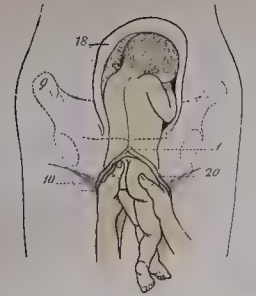

FIG. 45.—Passage of the breech through the vulva. Extraction with both hands applied to the fetal pelvis.

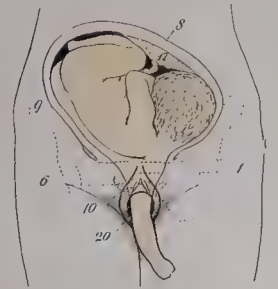

FIG. 51.—The right shoulder is wedged in the true pelvis. The head approaches the chest. Shoulder position.

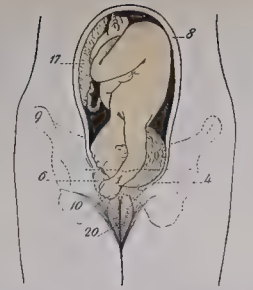

FIG. 46.—Oblique position La: Head to the left, back in front in prolapse of the right arm; secondary to a cranial position L, which is converted first into presentation of the anterior fontanel, then into a brow presentation, then into

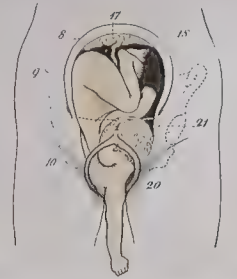

FIG. 52.—Birth of the head and shoulder conduplicato corpore (possible in the case of a premature or very much macerated fetus).

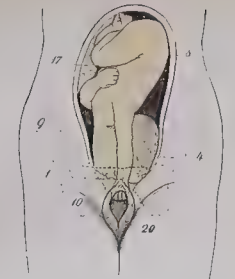

FIG. 47 Face position L, again by the brow catching on the edge of the pelvic inlet (iliopectineal line), and rotation of the head and trunk about their longitudinal axis into

FIG. 53.—Beginning of spontaneous evolution in oblique position La. The head is fixed and the back and breech successively glide past the head and are born.

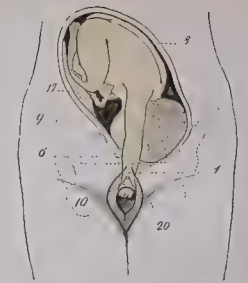

FIG. 48.—Oblique position La, back in front, head to the left. The head is arrested on the lateral wall of the pelvis.

FIG. 54.—The occiput catches behind the symphysis, the left arm is reflected over the head, and the lower extremities escape from the vulva.

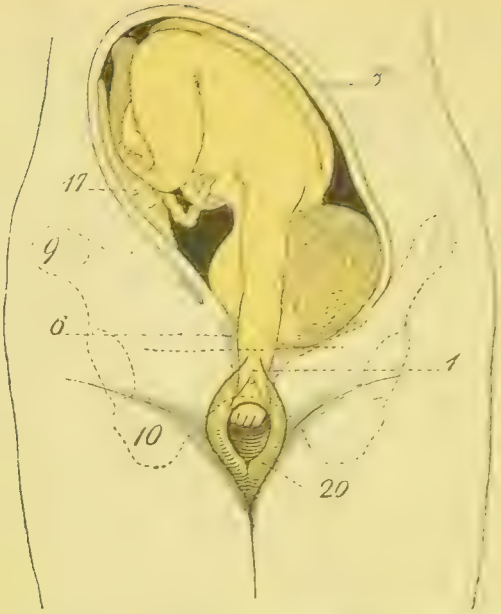

FIG. 48.—Oblique position I.a, back in front, head to the left. The head is arrested on the lateral wall of the pelvis.

FIG. 51.—The occiput catches behind the symphysis, the left arm is reflected over the head, and the lower extremities escape from the vulva.

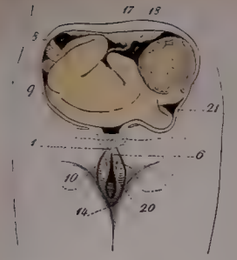

Fig. 55.—As a result of the uterine contractions, oblique position I.a is converted into a transverse position and then into a

Fig. 62.—The left shoulder appears behind and beneath the symphysis, followed by the escape of the right shoulder over the perineum. At the same time the elbows make their appearance. The figure shows the method of freeing the umbilical cord when the child is astride of it

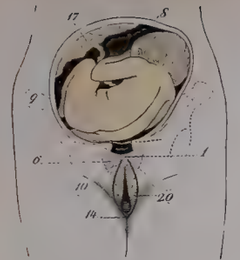

Fig. 56.—Breech position by spontaneous version.

Fig. 63.—The occiput passes behind the symphysis in the right oblique diameter: Occiput to the left and in front, chin to the right and behind. The nape of the neck catches on the symphysis.

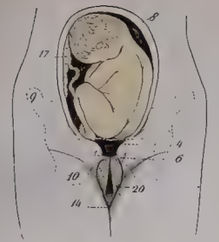

Fig. 57.—Becoming finally a breech-and-heel position I., about to enter the pelvic inlet. The fetal hips are in the left or second oblique diameter. (Back to the left.)

Fig. 64.—Escape of the face over the perineum.

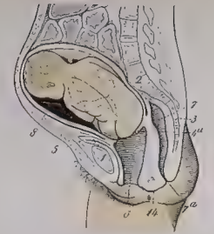

Fig. 58. Engagement of the breech in the left oblique diameter of the true pelvis. The left buttock in front and to the right by the side of the symphysis.

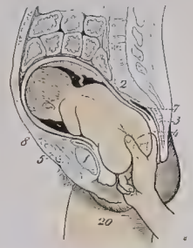

Fig. 65.—Extraction in breech position I.: Introduction of the index finger, which is hooked into the right posterior groin.

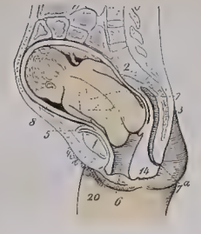

Fig. 59.—The fetal pelvis rotates about its anteroposterior diameter; in other words, the presenting left buttock descends.

Fig. 66.—If the posterior groin cannot be reached, a fillet (gauze) or the fingers are introduced into the anterior groin.

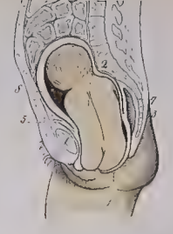

Fig. 60.—As the trunk rotates about its longitudinal axis, the right anterior buttock passes behind and beneath the symphysis

Fig. 67.—Extraction when the arms are reflected up along the sides of the head. This accident is prevented by pressing on the fundus with the flat of the hand

Fig. 61.—As the breech passes the vulva, the left buttock catches on the symphysis and the right buttock escapes over the perineum. At the same time the left buttock rotates forward and to the right. The birth of the feet follows. (Until the birth of the navel, expectant treatment, after that, extraction on account of the danger attending compression of the cord.)

Fig. 68.—Freeing the posterior right arm (to be seized like a pen), as soon as the angles of the scapula can be felt and seen. The arm is swept down over the face and chest

FIG. 68.—The child is pushed straight back into the uterus, so as to free the anterior arm. The child is then turned about its longitudinal axis, the operator applying his thumbs to the scapulæ, so that the back is brought first behind the symphysis and then into the right side of the mother. This brings the left arm of the child in front of the right sacro-iliac articulation, a position which is recognized by the disappearance of the folds in the region of the scapulæ (one-quarter rotation).



FIG. 70.—Busch's combined direct cephalic version with the entire hand in the uterus, when the os is completely dilated and the membranes are intact or have just ruptured, and there is an abundance of amniotic fluid. The internal right hand guides the head toward the pelvic inlet, while the external hand pushes the breech upward

FIG. 70.—Expression of the aftercoming head after Wigand-A. Martin-v. Winckel. The fingers are introduced into the mouth, not for the purpose of drawing the head down, but simply to direct it. The expression of the head is effected by the external hand.

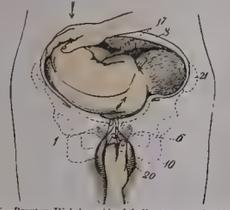

FIG. 77.—Braxton Hicks' combined indirect external and internal version of the breech before the os is completely dilated. (admits one or two fingers). First movement: The shoulders are pushed upward with one or two fingers.



FIG. 71.—Extraction of the aftercoming head after Mauriceau-Smellie-Veit, in two movements. (Danger of injuring the spinal cord. It is well to splint the cervical portion of the spinal column by placing the middle finger on the occiput.) The first movement consists in downward traction, then

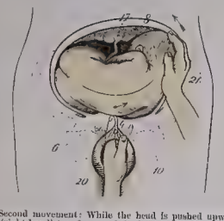

FIG. 78.—Second movement: While the head is pushed upward by the external (right hand) two fingers of the internal hand seize the knee.

FIG. 72.—The child is carried up against the mother's abdomen, so as to deliver the face over the perineum. It is best to combine the two methods by the help of an assistant. In funnel-shaped pelves and when the aftercoming head is low in the pelvis, the forceps is often less severe.



FIG. 79.—When the shoulder presents, v. Hecker's combined external and internal version, which is a continuation of Braxton Hicks' method, accomplishes the same object, as it is found that in such cases the knee is easily reached. Two or three fingers of the left hand are pushed past the presenting right shoulder (see Figs. 78, 79), seize the presenting (right) knee, and bring it down to the os, which is not completely dilated. A complete breech position is then effected by external pressure on the breech with the right hand.

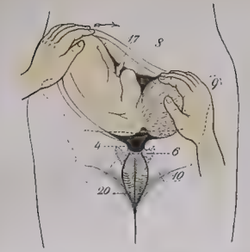

FIG. 73.—External version (Wigand) in oblique position I a (head to the left, back in front); when the membranes are intact and the os but slightly dilated.

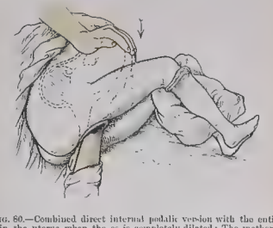

FIG. 80.—Combined direct internal podalic version with the entire hand in the uterus, when the os is completely dilated: The mother is placed on the side corresponding to the part to be brought down; the left arm is prolapsed; oblique position II a (head to the right, back in front). The right arm is introduced, the operator standing behind the woman's back

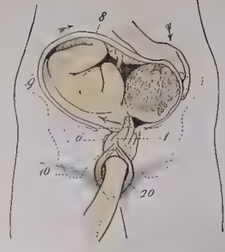

FIG. 74.—Braxton Hicks' combined indirect external and internal cephalic version (rarely applicable), before the os is completely dilated (admits one or two fingers). With the left hand the head is pushed into the pelvic inlet, while with the index and middle finger of the right hand the presenting right shoulder is pushed away from it.

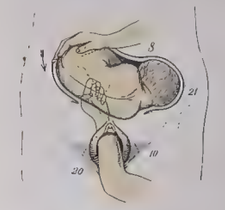

FIG. 81.—The same, with the woman in the dorsal position and the fetus in the oblique position I a. First movement: The presenting right knee is seized, while the breech is forced in the same direction by the external right hand.

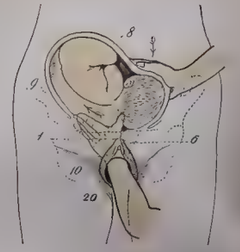

FIG. 75.—D'Outrepont's combined indirect cephalic version with the entire hand in the uterus, when the os is completely dilated and soon after the rupture of the membranes. The external hand forces the head into the pelvic inlet, the left hand pushes the presenting shoulder back

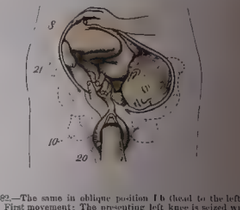

FIG. 82.—The same in oblique position I b (head to the left, back behind). First movement: The presenting left knee is seized with the left hand solely for the purpose of directing it toward the os, then

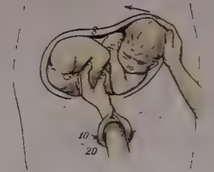

FIG. 83.—Second movement: The right knee is seized and version completed. The head is pushed upward from without with the right hand.

FIG. 91.—Unusual mode of escape of the head in breech positions; the chin catches on the symphysis, the face is therefore anterior.

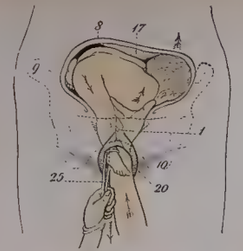

FIG. 84.—Madame Siegemund's method of internal version with two hands, especially adapted to cephalic positions with prolapse of the lower extremities. The presenting shoulder is pushed aside and the foot drawn down by means of a fillet (Fig. 89 should be studied immediately after Figs. 84 and 86).

FIG. 91.—Similar to the foregoing, the brow catches on the symphysis.

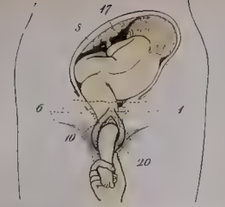

FIG. 85.—Right incomplete footling position (back to the right and in front). Produced by the method shown in Fig. 84. To extract the foot it is seized as follows: Use the hand of the same side of the body as the presenting foot (in this case the right); apply the thumb along the tendo Achillis, the index finger over the dorsum, and the middle finger to the plantar surface.

FIG. 92.—Braun's so-called combined Vienna method of expressing the aftercoming head. The ball of the right hand is applied to the mons veneris, while the thumb and index finger seize the back of the neck and shoulders like a clamp. The index finger of the left hand is applied to the lower jaw, and, by moderate traction assists the pressure of the fingers of the other hand. If the chin appears at the frenulum, the expression of the head is assisted by a lever movement accomplished by seizing both legs with the right hand (an assistant's if necessary) and sweeping the entire body up against the mother's chest. Only moderate force must be used in this method.

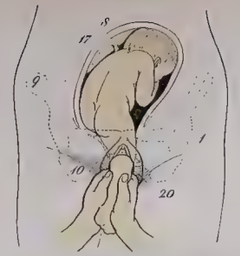

FIG. 86.—Subsequent steps in the extraction of the child by the leg and thigh.

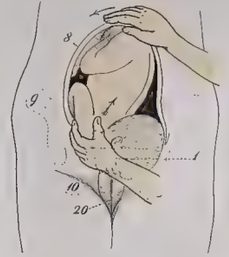

FIG. 93.—Face position I. (back to the left), chin posterior. This may be converted into a cranial position by Schatz's external method if the head is movable, the os not yet dilated, and the membranes intact. The left hand raises the right shoulder of the child and pushes it toward the occiput, thus converting the pathological lordosis of the vertebral column into a kyphosis, elevating the head and effecting a vertex presentation. The breech is pushed to the other side from without.

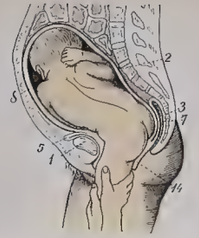

FIG. 87.—Extraction by the thigh; in left incomplete footling position (back to the left) the hips rotate into the right oblique diameter.

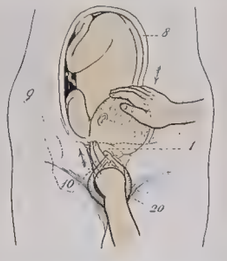

FIG. 94.—If the foregoing method fails, two fingers of the left hand are introduced as soon as the os is sufficiently dilated to admit two fingers, and the upper jaw or the entire face is pushed away from the pelvic inlet toward the side where the chin is found, the external right hand at the same time pressing the occiput in the same direction (Baudelocque).

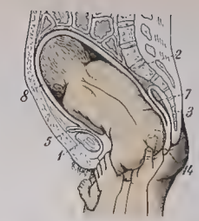

FIG. 88.—Extraction continued by hooking the right index finger into the posterior right groin.

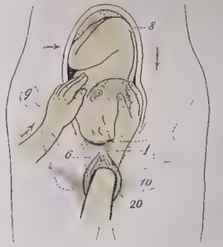

FIG. 95.—If this method also fails, finction until the membranes rupture; the right hand is then introduced into the uterus and the occiput rotated downward, while with the left hand the chest is pushed toward the other side (after Playfair, Partridge-Humphrey). For other combined methods with an assistant, see text (Thorn, Ziegenspeck).

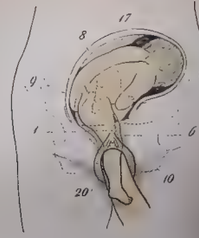

FIG. 89.—(Following Fig. 86.) The left hand (in right incomplete footling position) is introduced for the purpose of guiding down the posterior left leg, but only when the breech is still movable above the pelvic inlet. The subsequent course is shown in Figs. 14, 15, 16, etc., as a complete footling position.

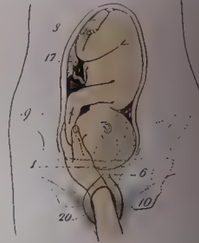

FIG. 96.—Repolition of a prolapsed right arm in cranial position I., to be attempted only when the arm has not yet reached the vulva, it should be pushed up above the pelvic inlet

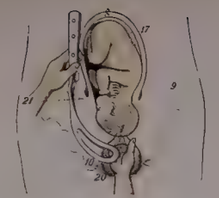

FIG. 97.—Introduction of the left (male) blade of the forceps (Naegele's forceps), held in the left hand and guided by the right, in front of the left sacro-iliac articulation, in cranial position I. (sagittal suture in the right or first oblique diameter).

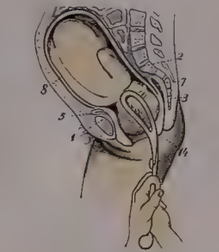

FIG. 104.—The same, seen in sagittal section: Sagittal suture in the anteroposterior diameter.

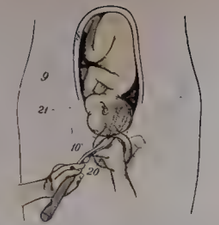

FIG. 98.—After the handle has been depressed, the left blade of the forceps lies in front of the left sacro-iliac articulation.

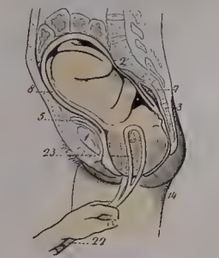

FIG. 105.—The head begins to appear at the vulva and to bulge the perineum forward. By elevating the handles the forceps is now gradually changed from position II. into position III. Lateral incisions if necessary.

FIG. 99.—Introduction of the right blade of the forceps, held in the right hand, guided by the left, first in front of the right sacro-iliac articulation and then by rotation behind the right iliopectineal tubercle. Rotation is effected by: (1) Depressing the handle; (2) Rotating the blade about its longitudinal axis; and (3) To the left (in cranial position I.). When the head is in the pelvic outlet the anterior blade of the forceps should be carried directly forward.

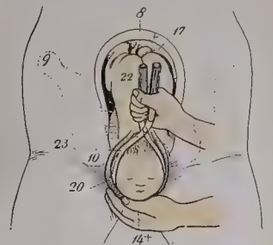

FIG. 106.—Traction, or rather lowering, in position III. The handles are carried obliquely upward toward the abdomen; the face is brought out over the perineum, which must be carefully protected. In primiparæ it is better to remove the forceps and deliver the face by Smellie-Ritgen's method (Fig. 11).

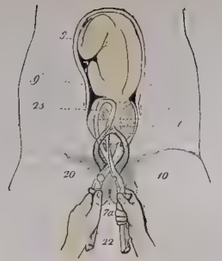

FIG. 100.—Locking of the forceps in position I.; the left blade lies in front of the left sacro-iliac articulation; the elbow is therefore in the left oblique diameter.

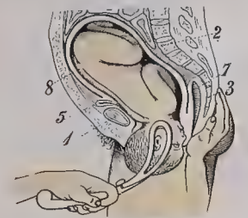

FIG. 107.—The same, seen in sagittal section. The shoulders are then delivered by alternately elevating and depressing the head, or after the manner shown in Fig. 108.

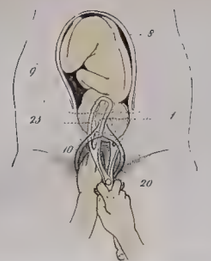

FIG. 101.—Trial traction in position I., obliquely downward when the head is high (at the level of the inlet). If the head is low, the forceps is immediately brought into the second position—horizontal. One finger is placed on the advancing head (seen in frontal section) to make sure that none of the soft maternal parts or a prolapsed umbilical cord has been included in the grasp of the forceps and to determine whether the head follows the pull of the instrument and rotates properly.

FIG. 108.—Extraction by hooking the right index finger into the posterior left axilla, combined with expression by pressure on the breech. The trunk is pushed downward and against the perineum (Kristeller's method).

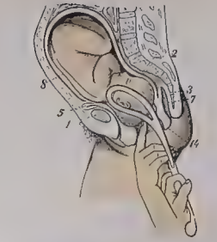

FIG. 102.—Trial traction in position I. (seen in sagittal section). The sagittal suture is rotated into the conjugate.

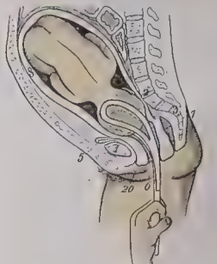

FIG. 109.—Sagittal view of the forceps in position in the left (II.) oblique diameter, when the head is high and in the proper position for the application of the forceps (greatest periphery at the pelvic inlet, os fully dilated). Cranial position I., sagittal suture in the transverse diameter. Frontal eminences at the level of the iliopectineal line or a little lower.

FIG. 103.—Traction in position II. after the head has descended. As soon as the head has entered the plane of pelvic contraction the handles are raised to the horizontal position. (They should be first loosened and reapplied to the sides of the head.)

FIG. 110.—Traction first in position I., in presentation of the anterior fontanel, then—

Fig. 111.—Direct change to position III. when the head appears at the vulva. The perineum must be protected.

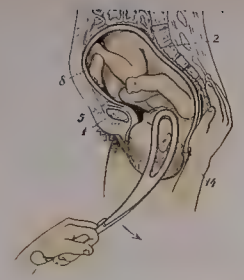

Fig. 112.—Finally, change to position II., in order to bring the sinciput out from under the symphysis.

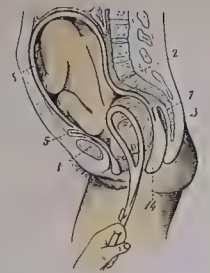

Fig. 113.—First pull in position II., and in face position I., chin anterior. The parietal eminences have passed the pelvic inlet, then—

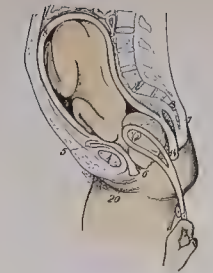

Fig. 111.—Traction in position I. to depress the chin, finally

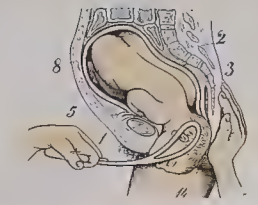

Fig. 115.—Position III., to draw the occiput over the perineum

Fig. 116.—Forceps delivery of the aftercoming head when it has passed the pelvic inlet and the mouth cannot be reached (see Figs. 70 to 72), employed instead of expression and extraction. The forceps is applied below, or rather behind, the fetal trunk, the latter being carried up toward the mother's abdomen. The perineum should be protected.

Fig. 117.—Perforation in cranial position II. (back to the right) with Levret's perforating scissors, using the finger as a guide.

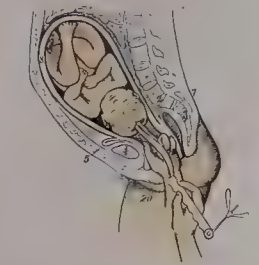

Fig. 118.—Introduction of the internal or first blade of Braun's craniochast into the perforated skull, using the left hand as a guide.

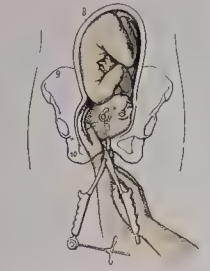

Fig. 119.—Introduction of the second blade, applied to the external surface of the occiput. By means of the thumbscrew the two handles are brought together so that the skull is crushed, reduced in size, and firmly seized for extraction.

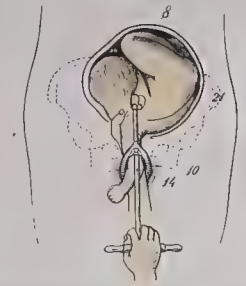

Fig. 120.—Decapitation with Braun's hook (prolapse of an arm); oblique position I.a

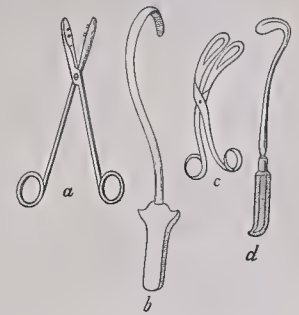

Fig. 121.—*a*, Bone forceps (in craniocleisis), *b*, sharp Levret's hook (extraction); *c*, forceps for the removal of placental remains and after abortion; *d*, Schultze's sickle-shaped knife (embryotomy).

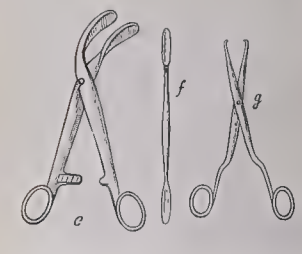

Fig. 122.—*e*, Extraction forceps (after craniocleisis, L. Winckel's pattern, improved by Mesnard); *f*, curet for use after abortion; and, *g*, double tenaculum to fix the cervix during curettage.

FIG. 116.—Forceps delivery of the aftercoming head when it has passed the pelvic inlet and the mouth cannot be reached (see Figs. 70 to 72), employed instead of expression and extraction. The forceps is applied below, or rather behind, the fetal trunk, the latter being carried up toward the mother's abdomen. The perineum should be protected.

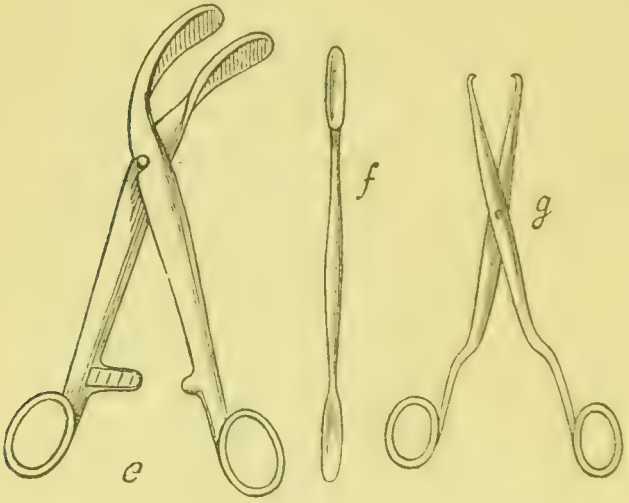

FIG. 122.—*e*, Extraction forceps (after cranioclasis, L. Winckel's pattern, improved by Mesnard); *f*, curet for use after abortion; and, *g*, double tenaculum to fix the cervix during curettage.

WELLCOME
LIBRARY
INSTITUTE